



**Roots & Wings Yoga Teacher Training Program
Anatomy Section, Weekend #2, The Extremities
May 14th, 2015
by Peter Sheridan**

TABLE OF CONTENTS

Fascia	1 - 3
Bones of wrist and hand	4
Joints of wrist	5
Muscles acting on wrist	6
Bones of arm	7 - 10
Joints of elbow	11 - 15
Muscles acting on elbow	16 - 19
Bones of feet	20 - 29
Bones of ankles	30
Joints of ankle	31 - 32
Muscles acting on ankle	33 - 37
Bones of legs	38
Joints of knee	39 - 41
Muscles acting on knee	42 - 45
Bibliography	46

HEALDSBURG PILATES & PERSONAL FITNESS

Peter Sheridan,
NSCA Certified Personal Trainer

Peter Sheridan, Certified Personal Trainer and owner of Healdsburg Pilates & Personal Fitness, graduated from Ohio University in 1990 with a BA in Psychology. Since returning from Central America upon completion of his service as a Peace Corps Volunteer, he has accomplished over 1,000 hours of continuing education in Pilates, movement re-education/rehabilitation, and sports-specific conditioning. After receiving his certification in 1997 and working in a large Sonoma County health club for three years, Peter established his Healdsburg Pilates-based fitness studio in 1999.

Peter has the good fortune to continue more than eighteen years of study under such Pilates luminaries as Jean Claude West and Mercy Sidbury, as well as with preeminent clinicians Mark Bookhout MS, PT and Karen Anderson PT, OCS. Peter is certified as a Pilates practitioner through the Physicalmind Institute®, and as a Personal Trainer through the National Strength and Conditioning Association. He is also an American Council on Exercise faculty member lecturer and workshop presenter.

Healdsburg Pilates & Personal Fitness
424-C Center Street
Healdsburg, CA 95448
peter@healdsburgpilates.com
(707) 433-2737

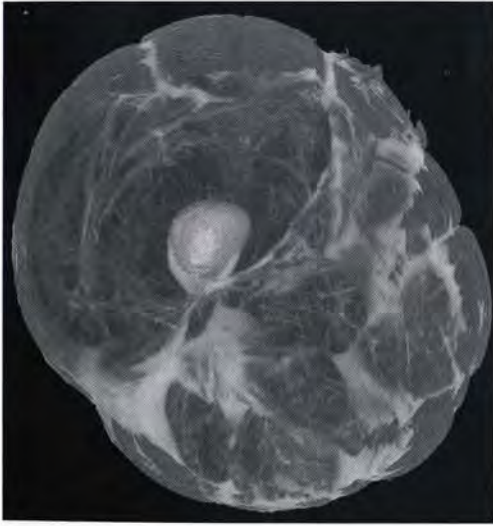


Fig. 1.17 A rendering of the fascial planes of the thigh by Certified Rolfer Jeffrey Linn, using data from the National Library's Visible Human Data Project. (Reproduced with kind permission from Jeffrey Linn.)



Fig. 1.18 The endomysial fibers that intimately relate each muscle fiber to its surroundings, and enable it to function with the rest to produce effective action. Each of these fascial fibers is part of and in contact with a body-wide continuum. (Reproduced with kind permission from Ronald Thompson.)

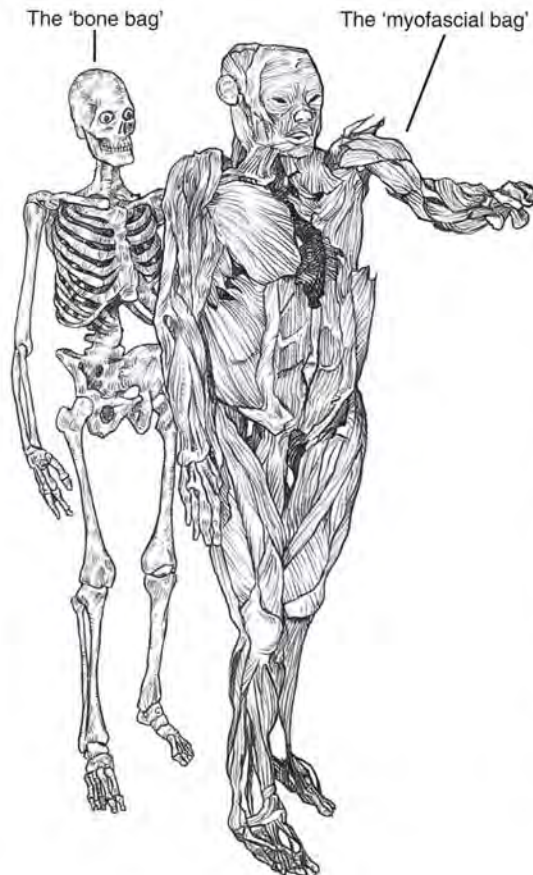

Fig. 1.32 This image, redrawn after a photo of the plastinated bodies in the Körperwelten project of Dr Gunter van Hagens, shows more clearly than any other the connected nature of the myofascia and the fallacy (or limitation, at least) of the 'individual muscle connecting two bones' image we have all learned. To prepare this specimen, Dr van Hagens removed the entire myofascial bag in large pieces and reassembled them into one whole. The actual effect is quite poignant; the skeleton is reaching out to touch the 'muscle man' on the shoulder, as if to say, 'Don't leave me, I can't move without you'. (The original plastinated anatomical preparation is part of the artistic/scientific exhibition and collection entitled Körperwelten (BodyWorld) which has appeared in several cities in Europe, and in Tokyo, but has yet to visit the USA. The author recommends this exhibition without reservation for its sheer wonder as well as the potency of its many ideas. Some taste of it can be obtained through visiting the website (www.plastination.com) and purchasing the catalog and/or the video, both of which are now available in English.)

The Anatomy Trains tracks are some of the common continuous lines of pull within this 'muscle bag', and the 'stations' are where the outer bag tacks down onto the inner bag of joint and periosteal tissue around the bones.

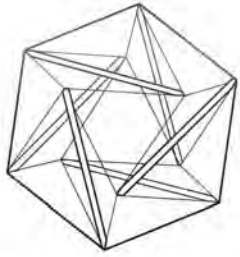


Fig. 1.33 In the class of structures known as 'tensegrity', the compression members (dowels) 'float' without touching each other in a continuous 'sea' of balanced tension members (elastics). (Reproduced with kind permission from Oschman 2000.)

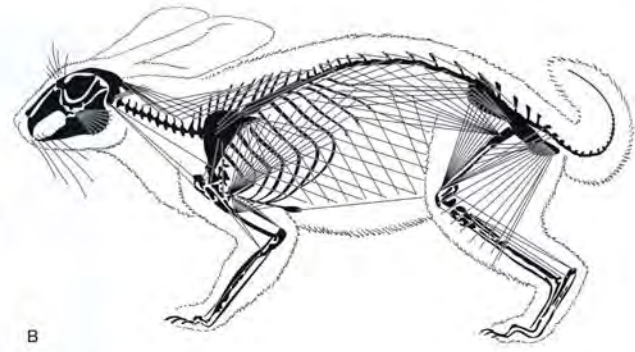
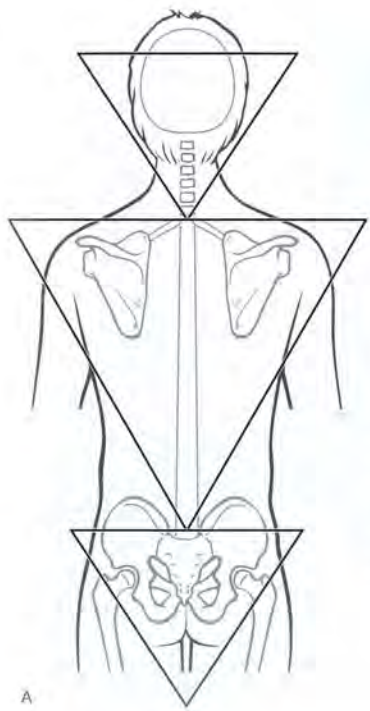
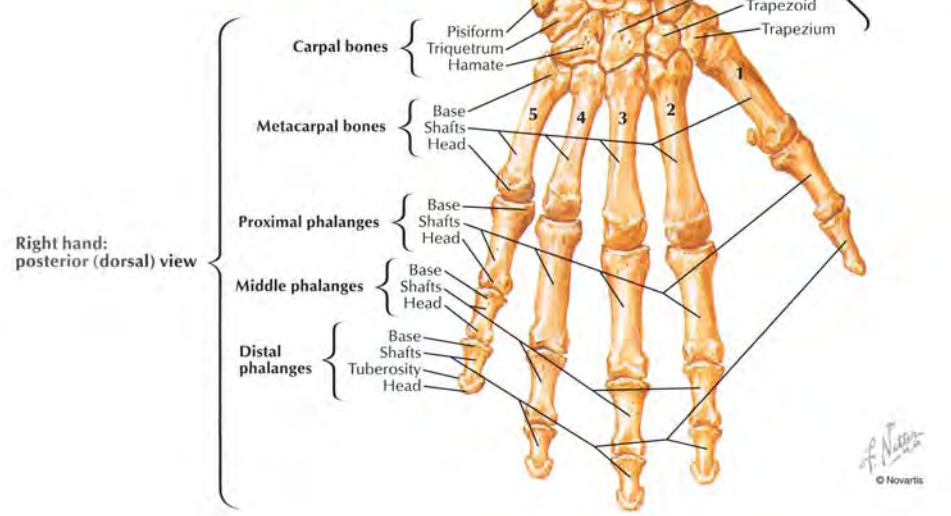
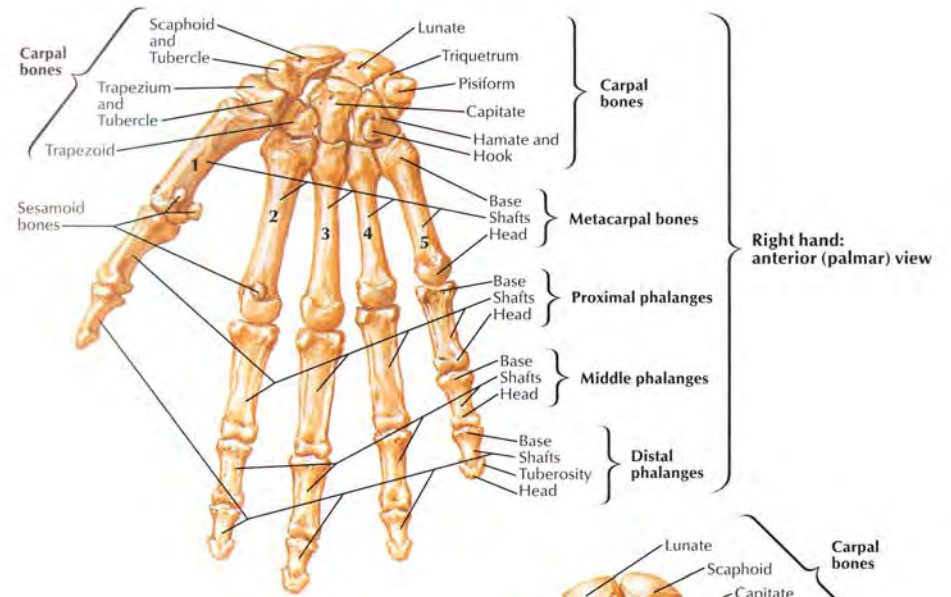


Fig. 1.34 Given the ease of building and simplicity of continuous compression structures, and given how many of them we make to live and work in, it is not surprising that the principles of tensegrity remained obscured for so long. **A.** shows a familiar continuous compression model of the body. (Redrawn with kind permission from Cailliet 1977.) **B.** approaches a tensegrity rendition of a rabbit. This was created by drawing a straight line from origins to insertions for the rabbit's muscles. (Reproduced with kind permission from Young 1981.) (Compare to Fig. In.2.)



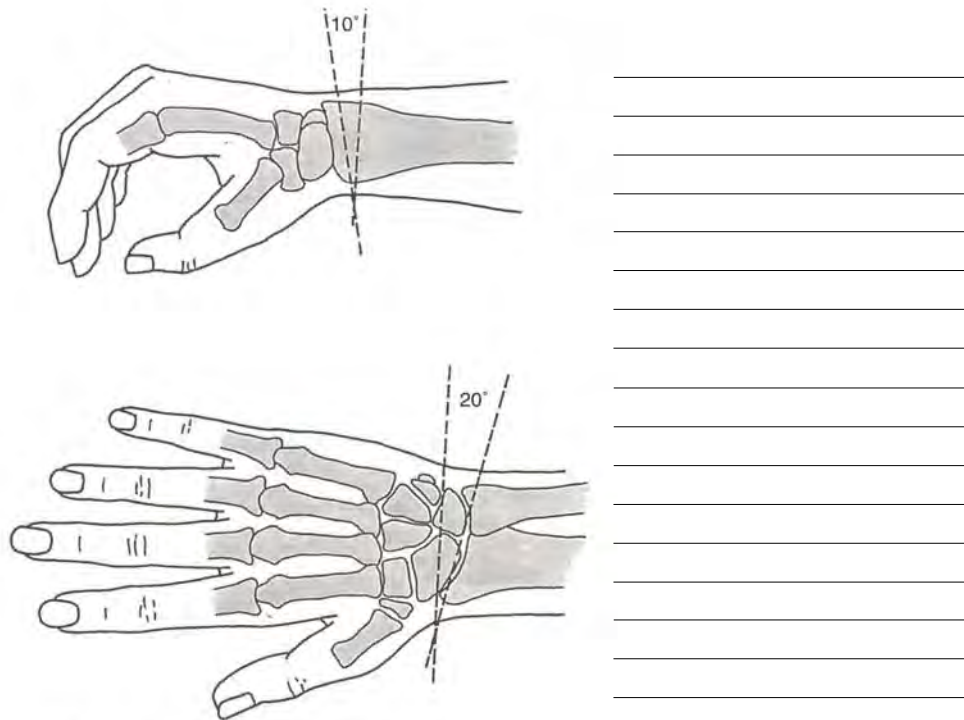
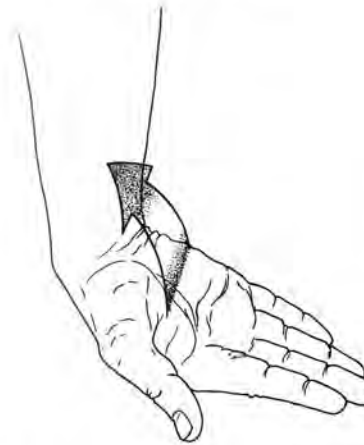

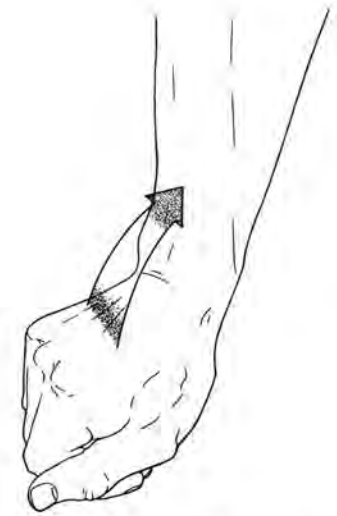
FIG. 11-3. Normal wrist alignment.

Movements

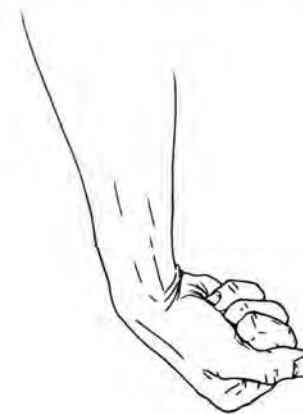Movements of the wrist



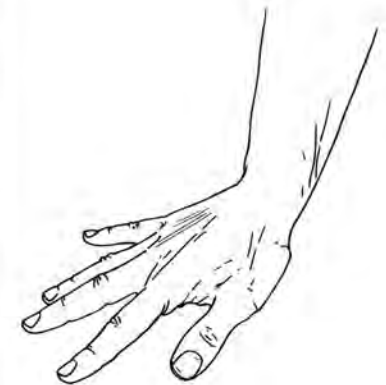In flexion of the wrist, the palm moves closer to the anterior surface of the forearm.



In extension of the wrist, the posterior surfaces of the hand and forearm move closer together.



The fingers tend to elongate during this movement, due to tightening of the extensor tendons. You can feel this tightening on the back of the hand when flexing the fingers.



In this case, the fingers tend to flex, due to tightening of the flexor tendons. You can feel these tendons on the palm when extending the fingers.

Flexion and extension of the wrist have roughly the same range of motion, usually 80° to 90° from anatomical position.

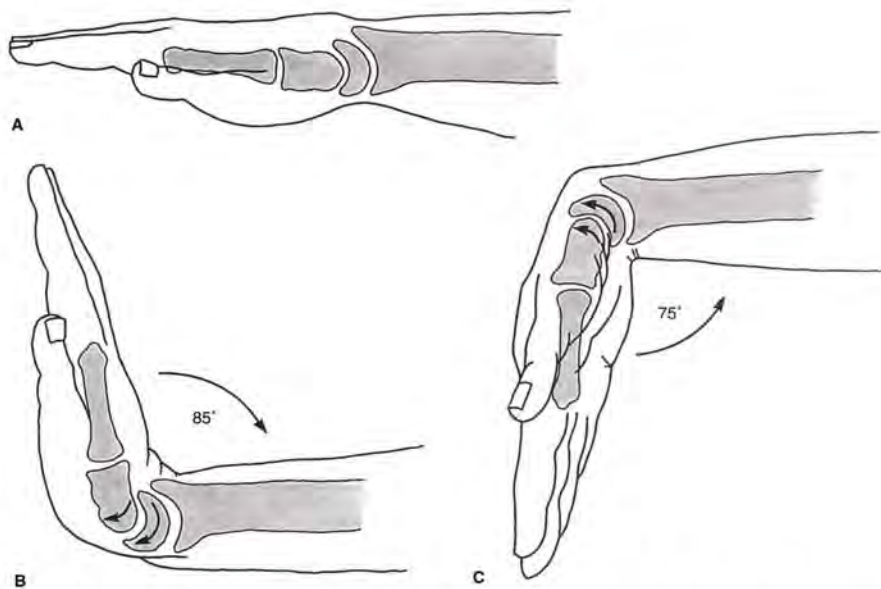


FIG. 11-18. Flexion-extension of the wrist showing neutral position (A), dorsiflexion with carpus moving palmarly and in supinatory rotation (B), and plamar flexion with carpus moving dorsally (C).

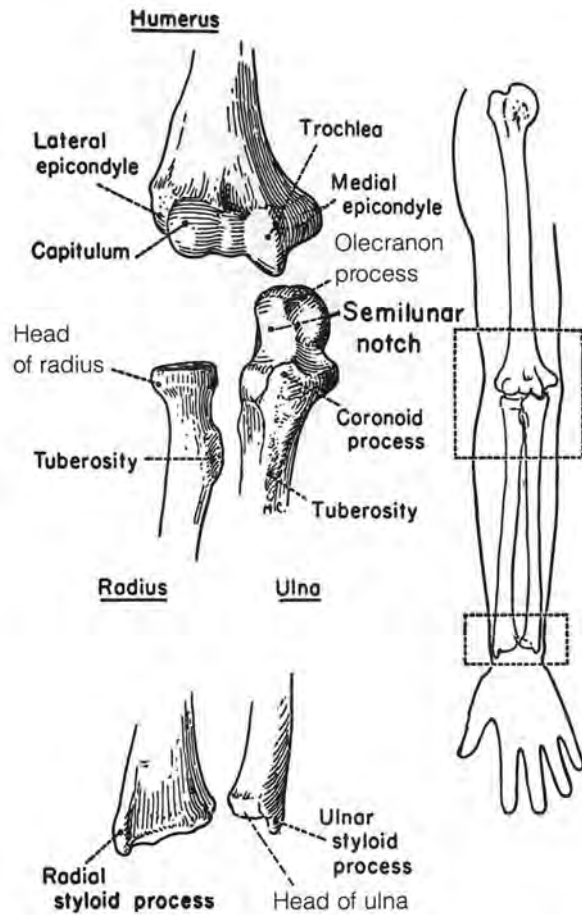
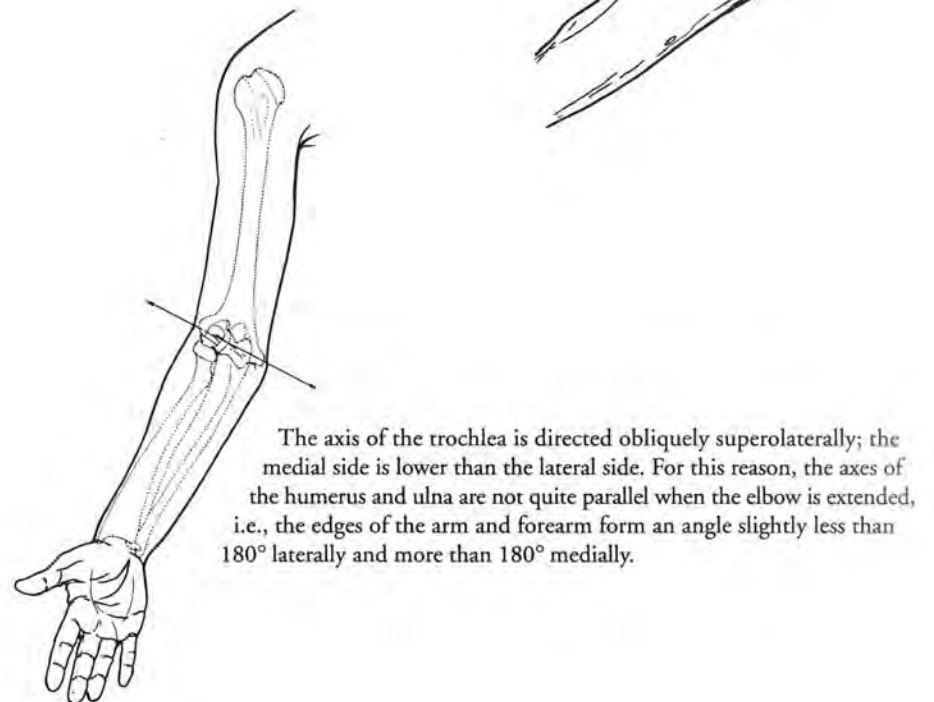
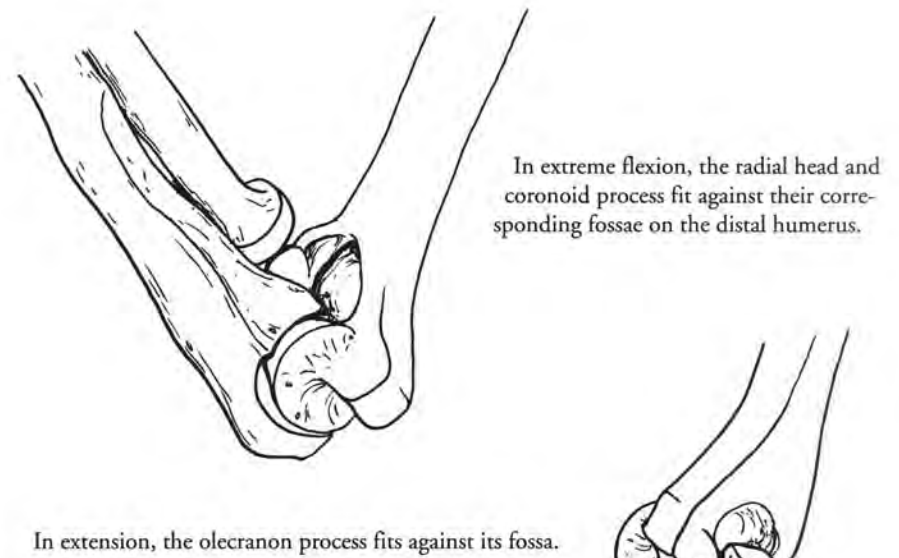


Figure 6.2. The elbow and radio-ulnar joints (right)



THE ARTICULAR SURFACES

(the numbers have the same meaning in all diagrams)

The distal end of the humerus has two articular surfaces (Fig. 3, according to Rouvière):

- The **trochlea** (2), (Fig. 4a) pulley-shaped with a central groove (1) lying in a sagittal plane and bounded by two convex lips (2).
- The **capitulum**, a spherical surface (3) lying lateral to the trochlea.

The complex formed by the trochlea and capitulum (Fig. 4) is like a *ball and spool threaded on to the same axis*. This axis constitutes, to a first approximation, *the axis of flexion and extension of the elbow*.

The following two points must be made:

The capitulum is not a complete sphere but a *hemisphere* (the anterior half of the sphere), placed, as it were, 'in front' of the lower end of the humerus. Therefore the capitulum, unlike the trochlea, does not extend posteriorly and stops short at the lower end of the humerus.

The *capitulum-trochlear groove* (Fig. 3) has the shape of a segment of a cone (4) with its wider base resting on the lateral lip of the trochlea. The usefulness of this capitulum-trochlear groove will emerge later.

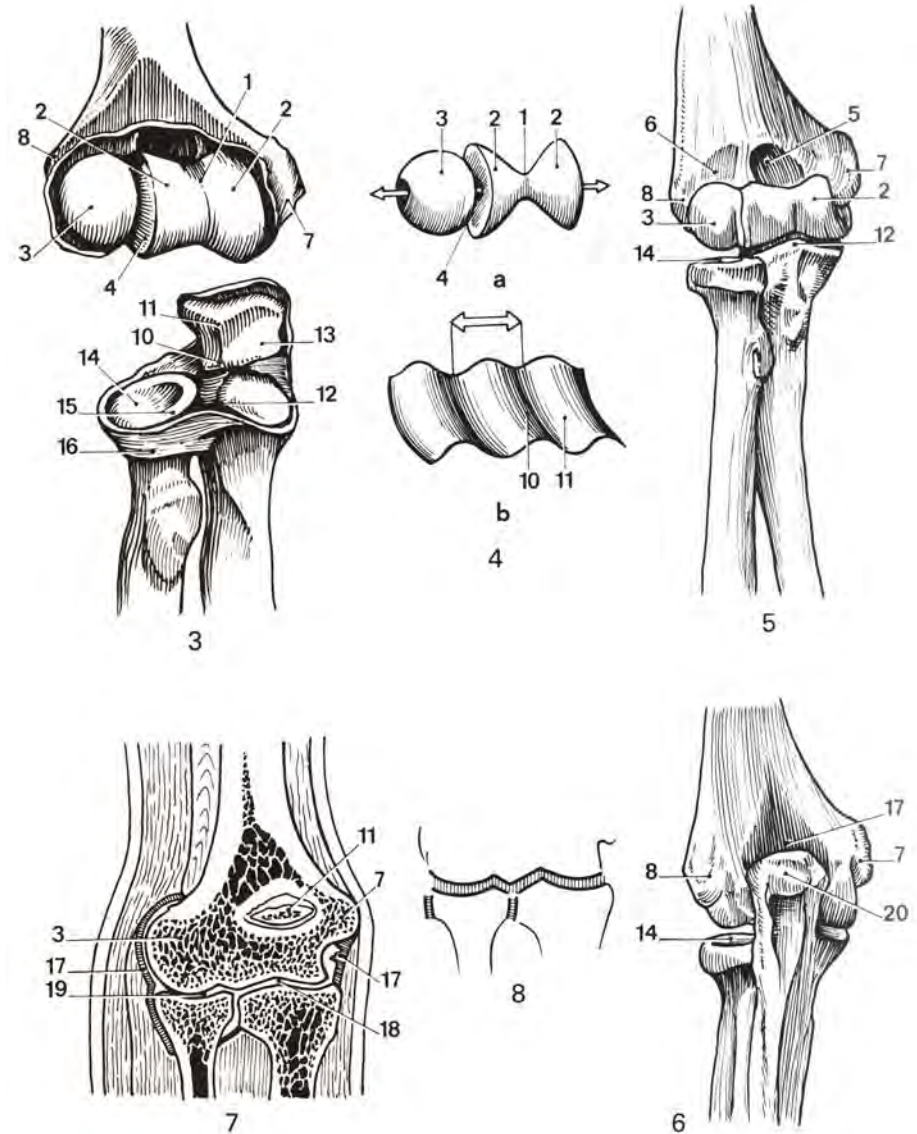
The proximal ends of the two bones of the forearm have *two* surfaces corresponding to those of the humerus:

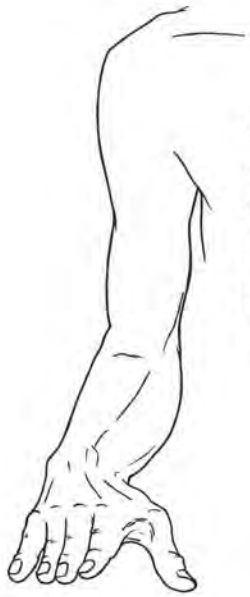- The **trochlear notch of the ulna** (Fig. 3), which articulates with the trochlea and *has the corresponding shape*. It consists of a longitudinal rounded ridge (10) extending from the *olecranon process* (11) superiorly to the *coronoid process* (12) anteriorly and inferiorly. On either side of this ridge, which corresponds to the trochlear groove, is a concave surface (13) corresponding to the lips of the trochlea. The articular surface is shaped like one unit of a *corrugated iron sheet* (white arrow), formed by a ridge (10) and two gutters (11) (Fig. 4b).
- The **cupped proximal surface of the head of the radius** (Fig. 3) with a *concavity* (14) corresponding to the convexity of the *capitulum humeri* (3). It is bounded by a rim which articulates with the capitulum-trochlear groove (cf. p. 83).

These two surfaces constitute in effect one articular surface owing to the annular ligament (16).

Figures 5 and 6 show **apposition of the articular surfaces**. Figure 5, seen from the front (*right side*), shows the olecranon fossa (5) above the trochlea and the radial fossa (6), the medial epicondyle (7) and the lateral epicondyle (8). Figure 6, seen from the back (*left side*), shows also the olecranon fossa (17) which receives the olecranon process (20).

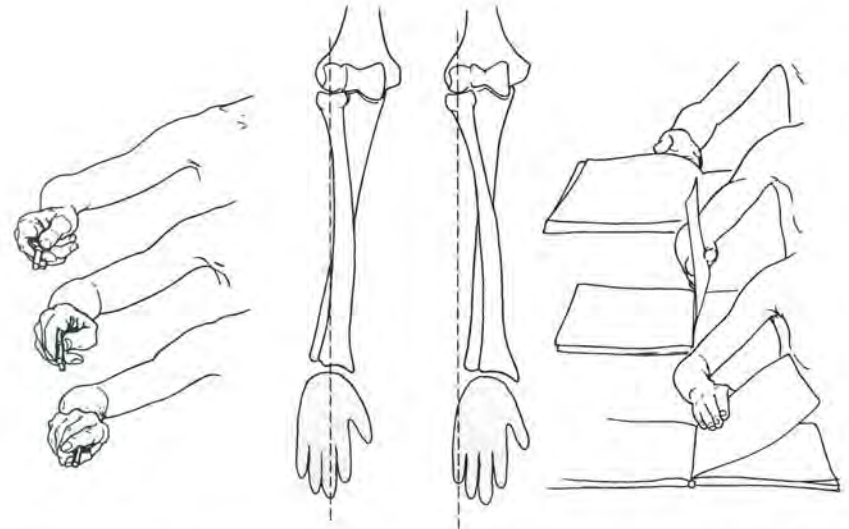
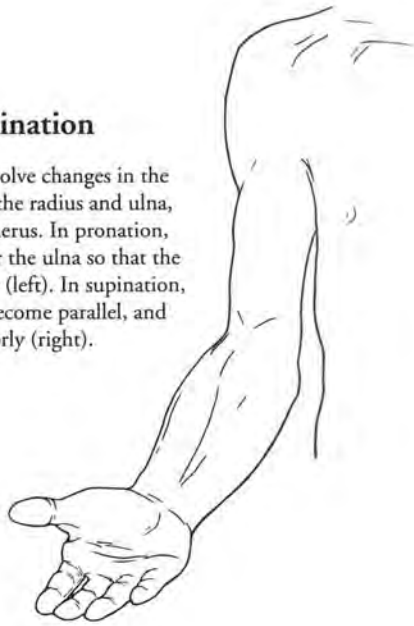
A coronal section taken through the joint (Fig. 7, according to Testut) shows that the capsule (17) invests a single anatomical joint cavity with two functional joints: the true elbow joint (Fig. 7, 18 & 19, and Fig. 8: vertical stripes) and the superior radio-ulnar joint (Fig. 8: horizontal stripes), essential for pronation-supination. The olecranon process is also seen (11), lying inside the olecranon fossa during extension.



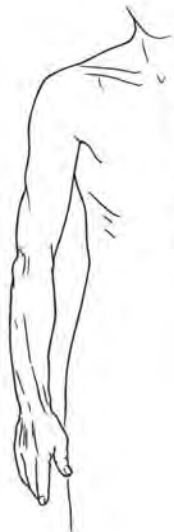

Pronation/supination

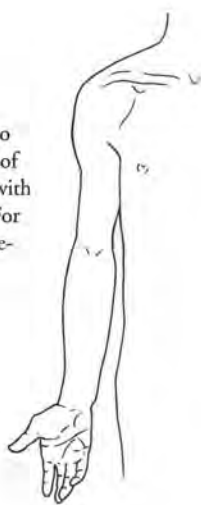
These movements involve changes in the relationship between the radius and ulna, not the ulna and humerus. In pronation, the radius crosses over the ulna so that the palm faces posteriorly (left). In supination, the radius and ulna become parallel, and the palm faces anteriorly (right).



There are two slightly different types of pronation. In the first (e.g., turning a key), the axis for movement of the hand passes through the middle finger, and the ulna moves slightly in conjunction with the radius. Anconeus is involved in this movement. In the second (e.g., flipping the page of a book), the axis of the hand passes through the fifth finger, and the ulna remains fixed.



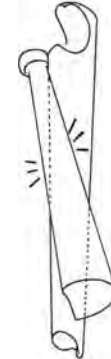
If the elbow is fully extended, it is easy to confuse pronation with medial rotation of the shoulder joint (left), and supination with lateral rotation of the shoulder (right). For this reason, it is best to study these movements with the elbow flexed.



The ulna and radius, in anatomical position, are both concave anteriorly.



This curvature allows the radius to cross over the ulna during pronation.



If both bones were straight, they would contact each other too soon and normal pronation would be impossible.

Fractures or other injuries can alter these curvatures and thereby interfere with pronation. This is a point of concern in certain disciplines (e.g., martial arts) involving unusual stresses on the forearm.

THE DYNAMICS OF THE SUPERIOR RADIO-ULNAR JOINT

(in Figs. 32 to 35 the upper row (a) refers to supination and the lower row (b) to pronation; the numbers have the same meaning throughout)

The **main movement** (Fig. 32) is *rotation of the head of the radius (1) about its axis xx' within the fibro-osseous ring (2), formed by the annular ligament and the radial notch of the ulna. This movement is limited (Fig. 33) by the tension developed in the quadrate ligament, which therefore acts as a brake (3).*

The head of the radius is not quite cylindrical but slightly oval: its great axis, lying obliquely antero-posteriorly (a, Fig. 34) (Fig. 29a), measures 28 mm and its short axis 24 mm. This explains why the annular cuff of the radial head cannot be entirely bony and rigid: *the annular ligament, which constitutes about three-quarters of the cuff, is flexible and allows some stretching*, while holding the head in perfect fit.

There are **four accessory movements** related to the radio-ulnar joint:

1. The *cup-shaped surface of the radial head (1) rotates in relation to the capitulum humeri (Fig. 36).*

2. The *bevelled ridge of the head of the radius (2) (cf. p. 82) glides in contact with the capitulo-trochlear groove of the humerus (Fig. 36).*

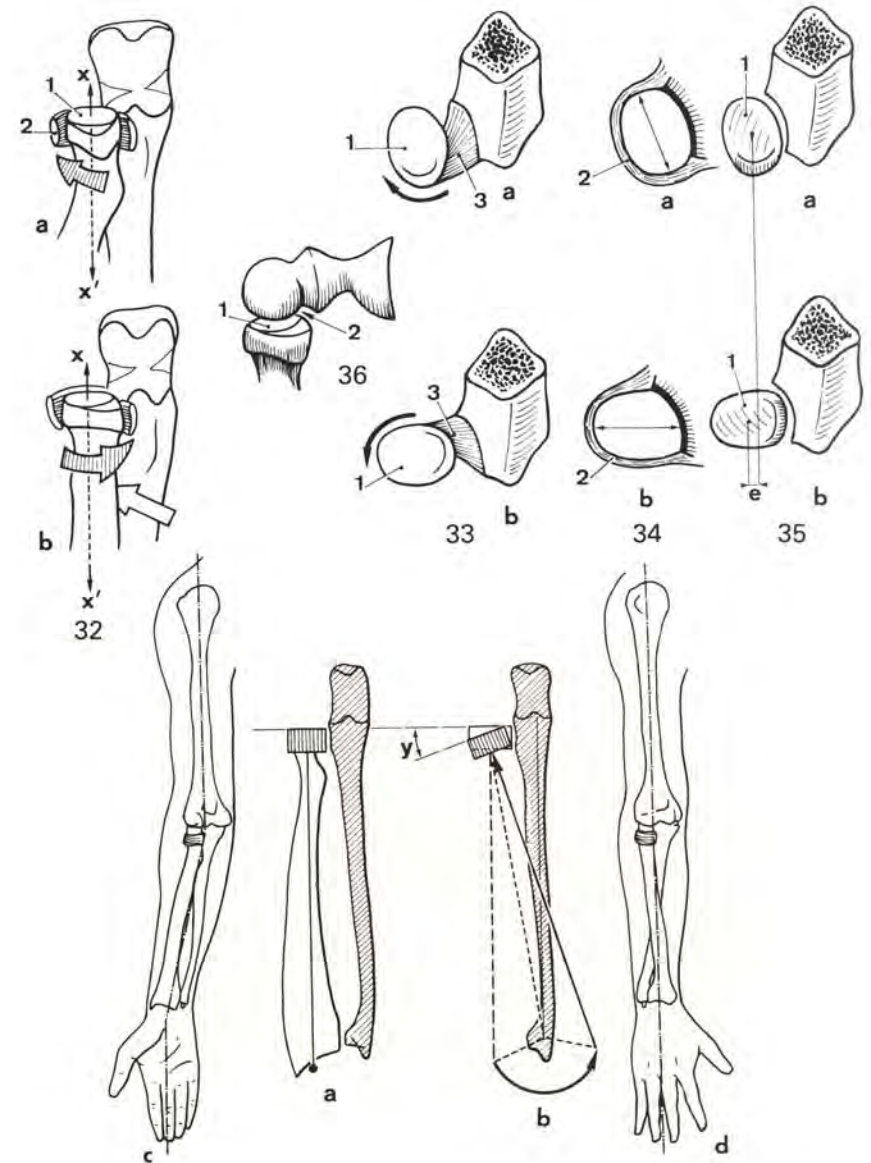
3. *The axis of the radial head is displaced laterally during pronation (Fig. 35) because of the oval shape of the head. During pronation (b) the great axis of the radial head comes to lie transversely so that the long axis of the radius xx' is displaced laterally by a distance e equal to half the difference between the two axes of the radial head, i.e. 2 mm. This lateral displacement has great mechanical significance: it allows room for the *medial movement of the radial tuberosity*, into which the supinator is inserted. The white arrow (Fig. 32b) shows this movement of the radial tuberosity 'between' the radius and the ulna.*

4. *The plane of the proximal surface of the radial head is tilted distally and laterally during pronation (Fig. 37). This is due to rotation of the radius about the ulna during pronation as follows:*

- At the beginning of pronation, i.e. while still in supination (a), the long axis of the radius is vertical and parallel to that of the ulna;
- At the end of pronation, the long axis now runs obliquely distally and medially so that the plane of the radial head, which is perpendicular to this axis, is now tilted distally and laterally at an angle y with the horizontal plane.

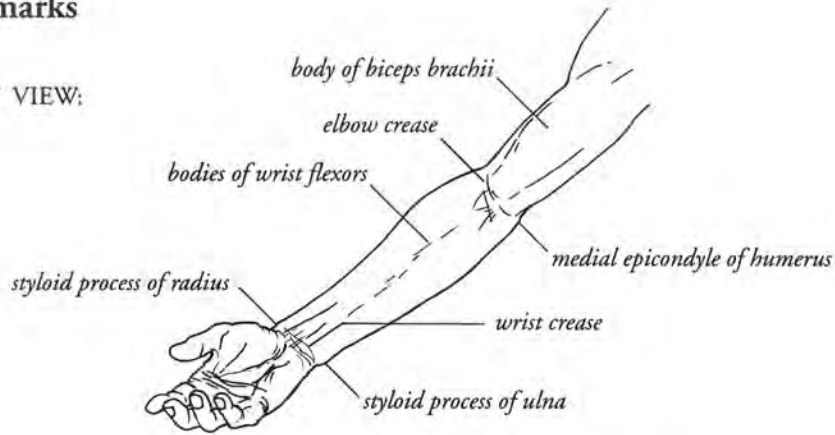
During pronation the long axis of the radius has 'swept' over part of the surface of a cone whose axis (finely hatched) is the same as *the common axis of the two radio-ulnar joints.*

The carrying angle of the arm (cf. also Fig. 26, p. 85), which is prominent during supination (c), becomes negligible during pronation (d) owing to the change in direction of the radial axis with the result that *the long axes of the arm and forearm become continuous.*

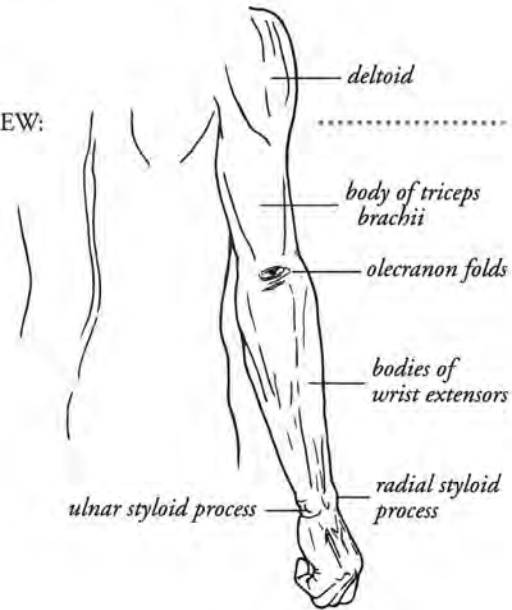


Landmarks

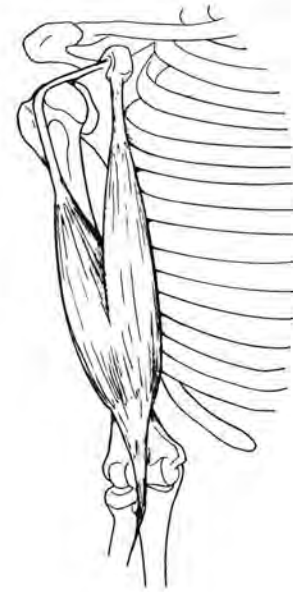
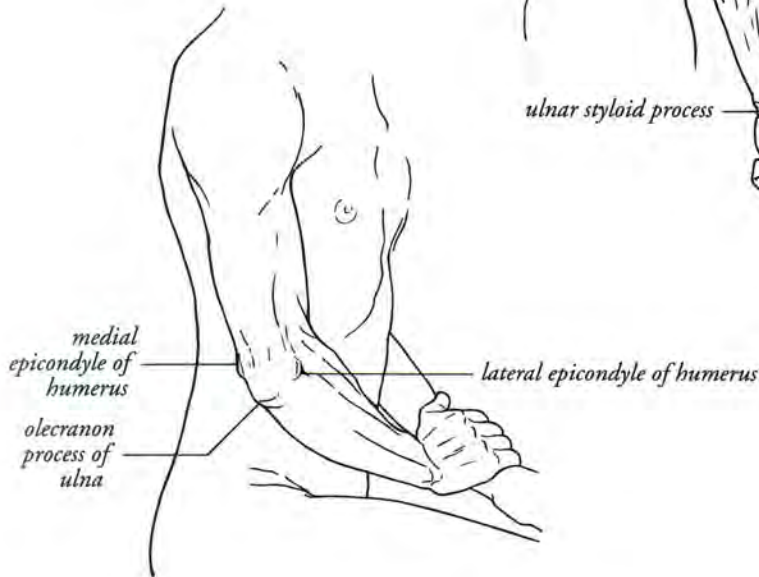
FRONT VIEW:



BACK VIEW:



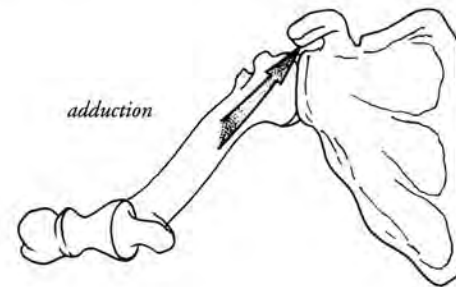
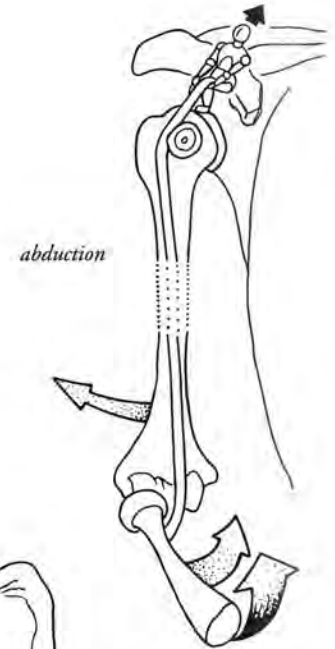
BACK VIEW,
ELBOW FLEXED:



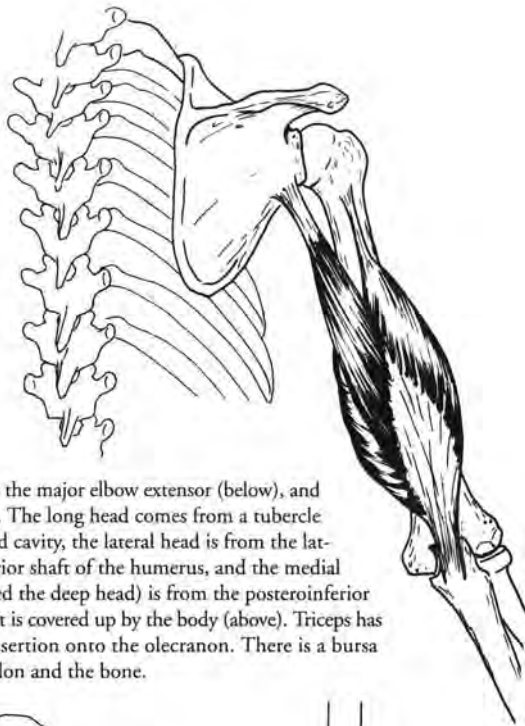
Biceps brachii has two origins: a short head from the coracoid process (fused with coracobrachialis) and a long head from a tubercle above the glenoid cavity. It inserts on the radial tuberosity and the **bicipital aponeurosis**, a broad fibrous sheet which blends with the deep fascia of the medial forearm.

Biceps is primarily a flexor and supinator of the forearm (see p. 139). However, the long and short heads are also involved in abduction...

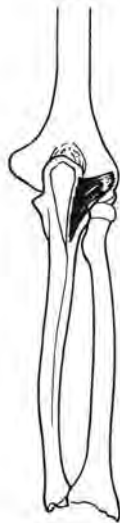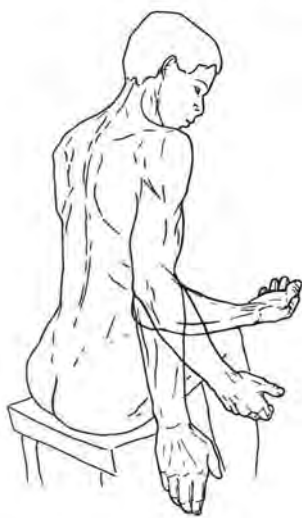
...and adduction of the arm, respectively.



Triceps brachii is primarily a forearm extensor (see p. 140). However, one of its three origins (the long head) is from the scapula, and this part of the muscle assists in adduction of the arm.



Triceps brachii is the major elbow extensor (below), and has three origins. The long head comes from a tubercle below the glenoid cavity, the lateral head is from the lateral posterosuperior shaft of the humerus, and the medial head (better called the deep head) is from the posteroinferior humerus, where it is covered up by the body (above). Triceps has a single broad insertion onto the olecranon. There is a bursa between the tendon and the bone.

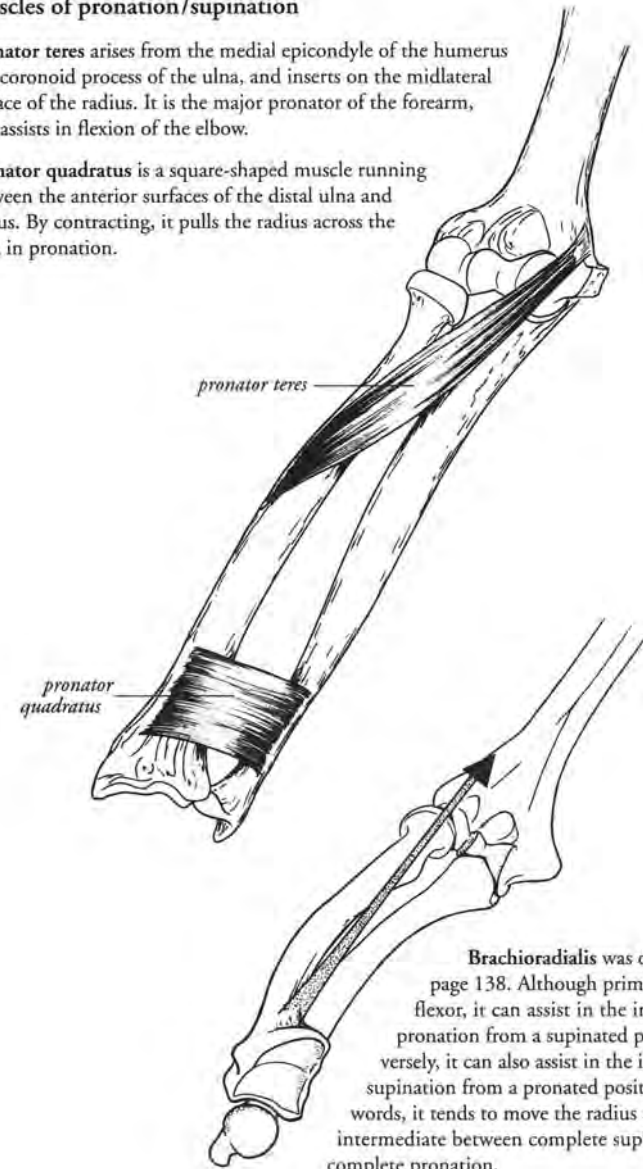


Anconeus is a small muscle running from the lateral epicondyle to the lateral olecranon and superior ulna. It assists the triceps in extension, and also plays a small role in pronation (see p. 144).

Muscles of pronation/supination

Pronator teres arises from the medial epicondyle of the humerus and coronoid process of the ulna, and inserts on the midlateral surface of the radius. It is the major pronator of the forearm, and assists in flexion of the elbow.

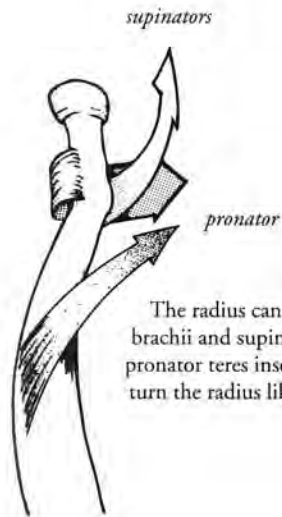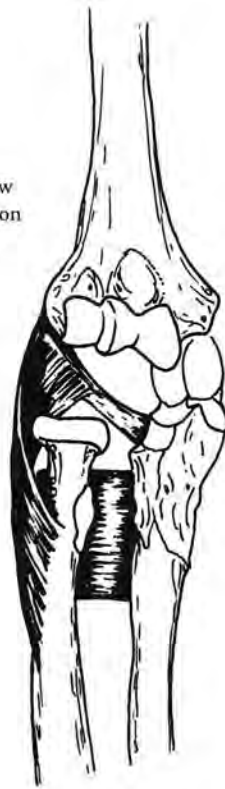Pronator quadratus is a square-shaped muscle running between the anterior surfaces of the distal ulna and radius. By contracting, it pulls the radius across the ulna in pronation.



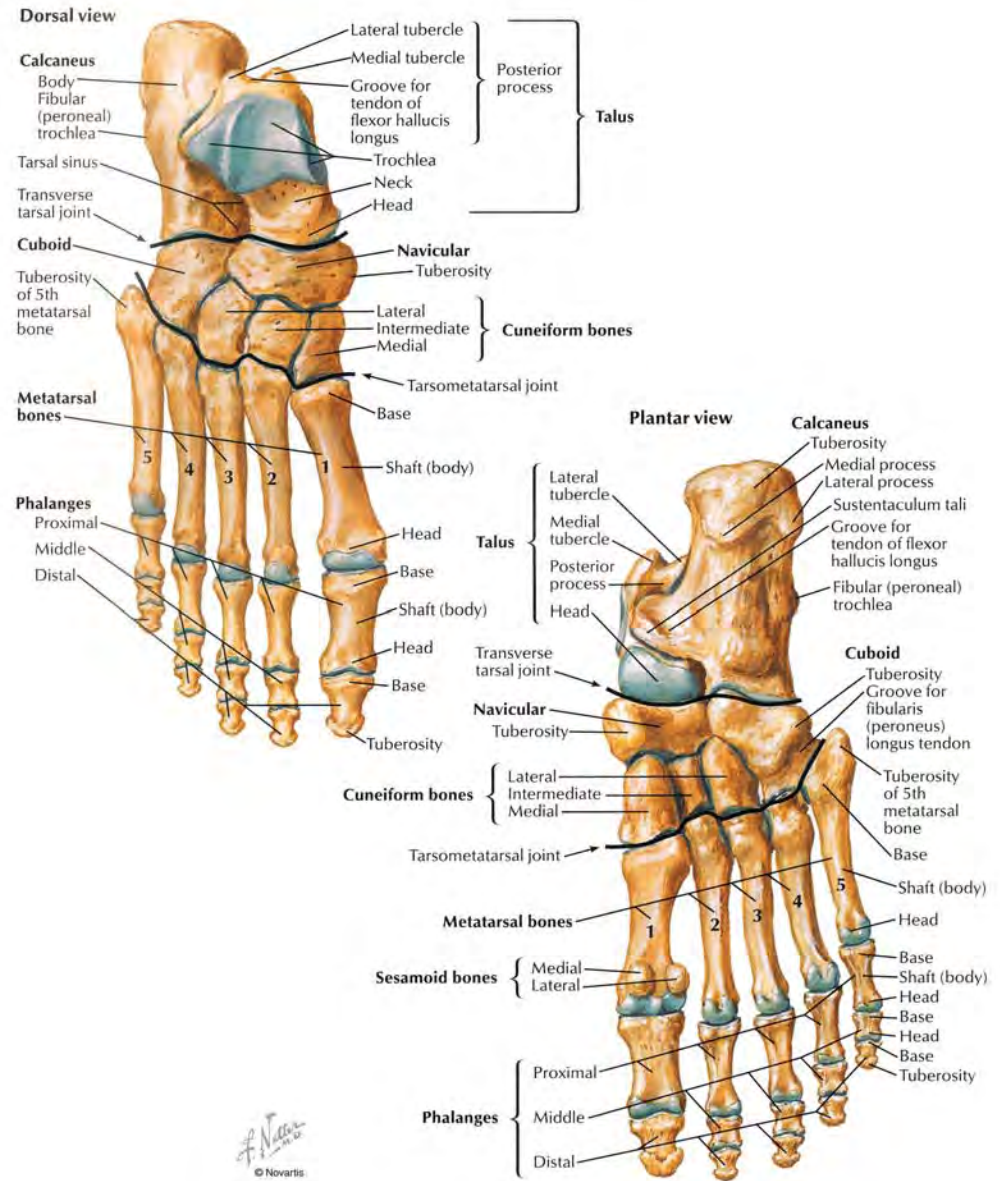
Brachioradialis was described on page 138. Although primarily an elbow flexor, it can assist in the initial stage of pronation from a supinated position. Conversely, it can also assist in the initial stage of supination from a pronated position! In other words, it tends to move the radius to a position intermediate between complete supination and complete pronation.

Biceps brachii was described on page 139. Besides its role as an elbow flexor, it is also an important forearm supinator because of the location of its insertion (on the posterior aspect of the radial tuberosity); i.e., it "uncrosses" the upper radius from a pronated position.

Supinator originates in two layers. The superficial layer is from the lateral epicondyle of the humerus; the deep layer is from the "supinator ridge" located just below the posterior radial notch of the ulna. This muscle wraps around the radius, inserting between the neck and the insertion of pronator teres (right). As you may have guessed by its name, it supinates the forearm; it cooperates with biceps brachii in returning the proximal radius from a pronated position to anatomical position.



The radius can be visualized as having a "supinating curve" (with biceps brachii and supinator inserting near the top), and a "pronating curve" (with pronator teres inserting near the top). By contracting alternately, these muscles turn the radius like a crank.



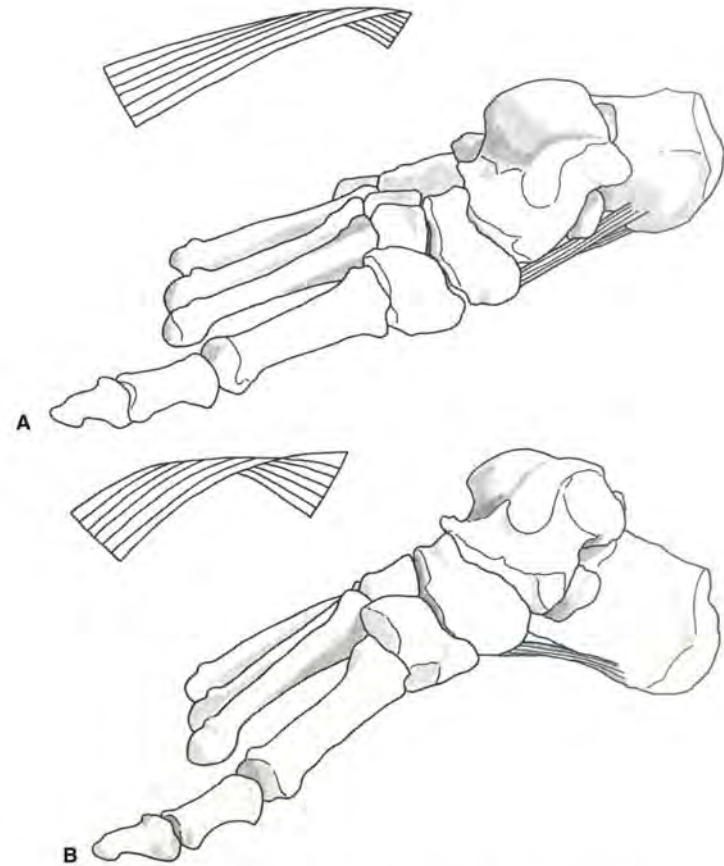
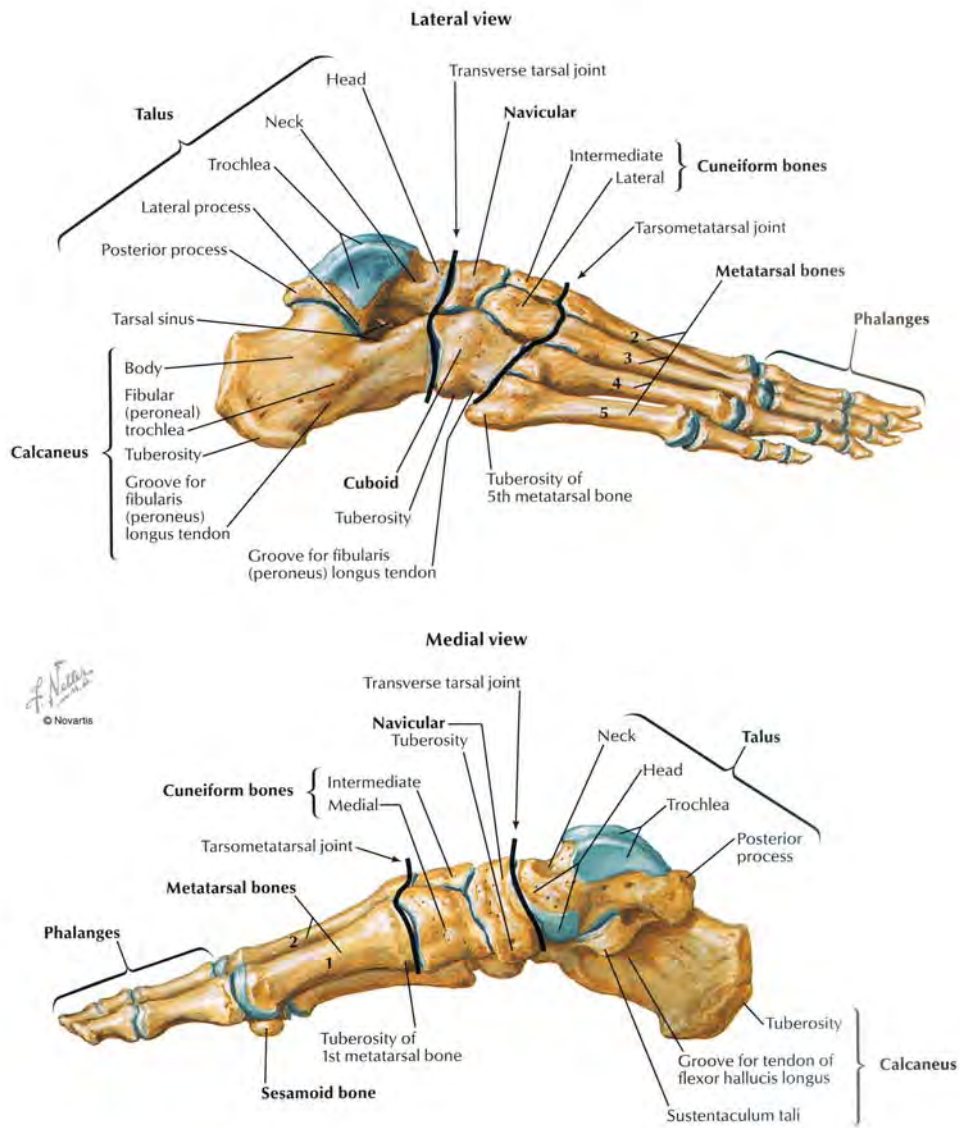


FIG. 14-25. The medial arch. **(A)** When it is allowed to “untwist,” the arch flattens; **(B)** when the medial arch is “twisted” the arch increases.

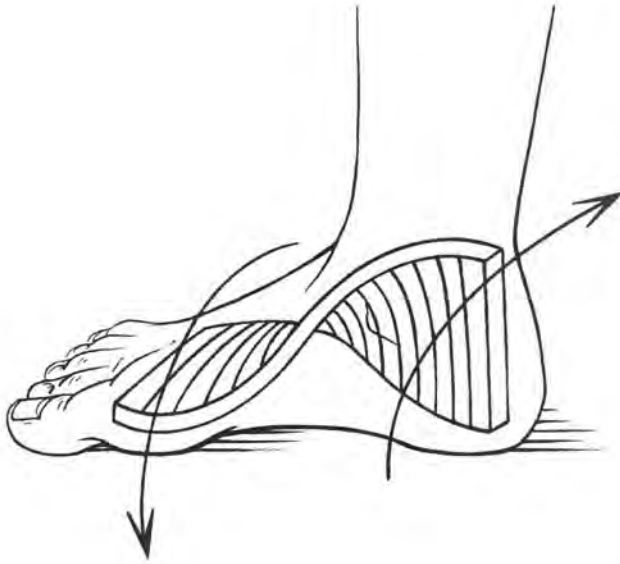


Figure 12.25 The foot can be visualized as a twisted rectangular plane.

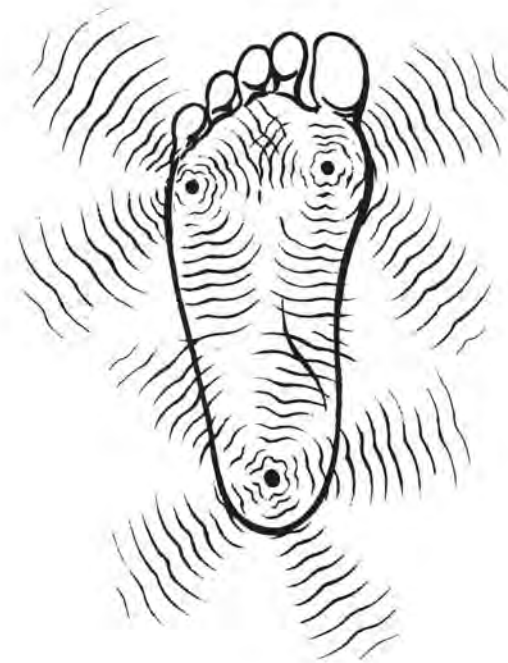


Figure 12.27 Visualize the three main contact points of the foot with the floor as a tripod.

GENERAL ARCHITECTURE OF THE PLANTAR VAULT

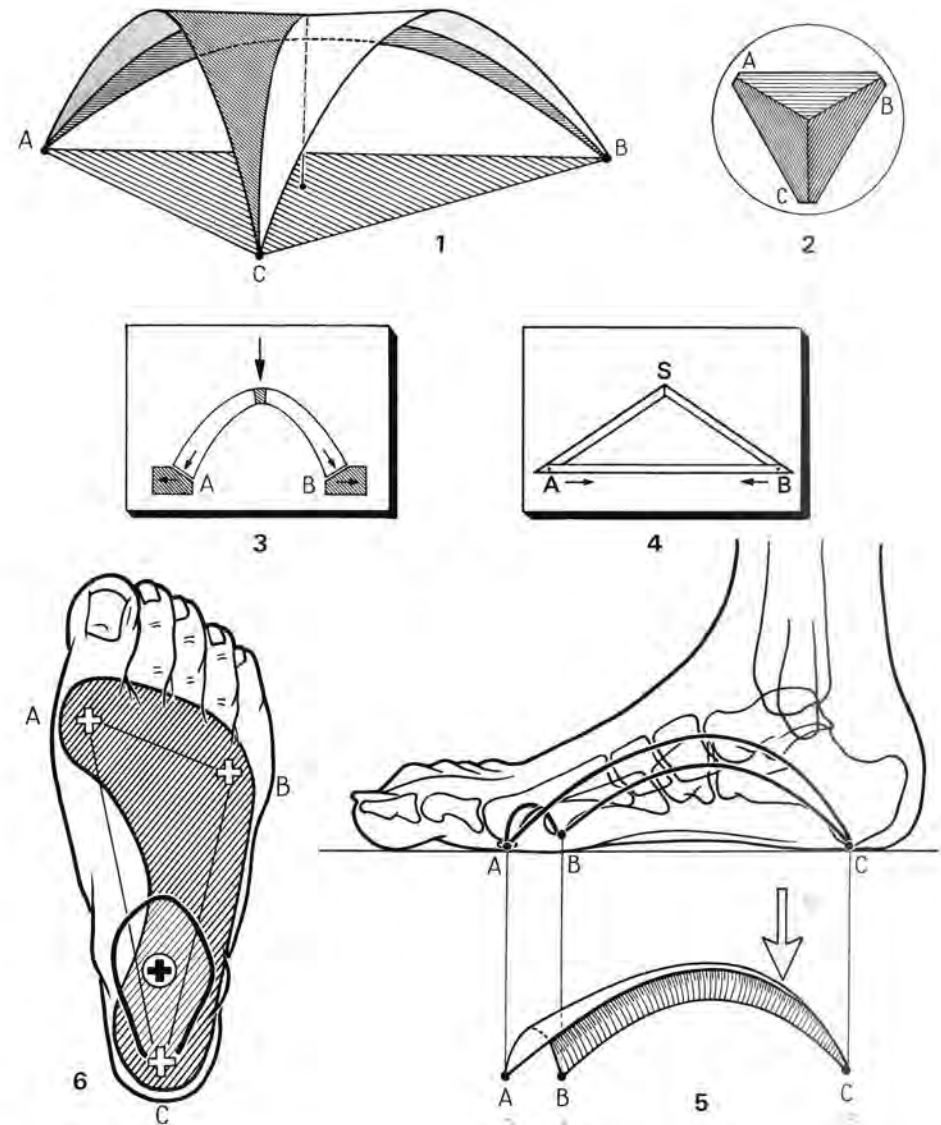
Viewed as a whole, the plantar vault can be compared with an **architectural vault supported by three arches** (fig. 1). It rests on the ground at three points A, B and C (fig. 2) which lie at the corners of an equilateral triangle (fig. 2). Between two consecutive supports AB, BC or CA stretches an arch which constitutes one of the sides of the vault. The weight of the vault is applied (fig. 3) at the *keystone* (arrow) and is distributed to the supports A and B (known as the *abutment piers* of the arch) by the two buttresses.

Following Lapidus' lead, Doncker and Kowalski reject this view of the plantar vault as too static and they consider, undoubtedly with some justification, the lateral and anterior arches to be figments of the imagination. They prefer to compare the foot to a *truss* (fig. 4), consisting of two *rafters* (SA and SB) joined at the ridge (S) and kept apart by a *binder* (AB), which prevents collapse of the triangle when a load is applied at the ridge. Thus the foot would consist only of a single truss with a primary binder provided by the powerful plantar ligaments and the plantar muscles and two secondary lateral binders corresponding to the classic medial and lateral arches. This conception of the foot corresponds more closely to the anatomical reality, especially as regards the ligaments and muscles, which can be effectively compared to binders. However, the terms 'vault' and 'arches' are so evocative and so entrenched in usage that it is preferable to continue using them along with 'truss' and 'binders'. As is often the case in biomechanics, two notions, which at first appear contradictory, are not mutually exclusive and contribute to a better understanding. We will therefore continue to use 'plantar vault' and 'arches'.

The **plantar vault** (fig. 5: seen from the medial aspect; the structures are shown as transparent) does not form an equilateral triangle but, as it contains three arches and three supports, its structure is comparable. Its supports (fig. 6: seen from above; the foot is assumed to be transparent) lie within the zone of contact with the ground or the **footprint** (striped). They consist of the *head of the first metatarsal* (A), the *head of the fifth metatarsal* (B) and the *posteromedial and lateral tubercles of the calcaneus* (C). Each support is shared by two adjacent arches.

Between the two *anterior* supports A and B stretches the **anterior arch** which is the shortest and the lowest. Between the two *lateral* supports B and C lies the **lateral arch** of intermediate length and height. Finally between the two *medial* supports C and A lies the **medial arch** the longest and highest and also the most important of the three during static support of the body and during movements.

The shape of the plantar vault (the lower part of fig. 5) therefore resembles that of a jib swollen by the wind. Its top is distinctly displaced posteriorly and the weight of the body is applied on its posterior slope (arrow) at a point (black cross in fig. 6) located at the centre of the instep.



FLAT FOOT (PES PLANUS)

The collapse of the plantar vault is due to *weakness of its natural means of support*, i.e. muscles and ligaments. The ligaments by themselves are capable of maintaining the integrity of the vault for a short period since the footprint of an amputated leg is normal except if the ligaments have been previously cut. In life however, if the muscular support fails, the ligaments become stretched eventually and the vault collapses for good.

The flat foot is therefore due mainly to muscular insufficiency (fig. 78): insufficiency of the tibialis posterior (4) or, more commonly of the **peroneus longus** (5). If the foot is not supporting the body the foot shows a varus deformity (fig. 79) because the peroneus longus is an abductor. On the other hand, when the weight of the body is applied to the foot (fig. 80) the medial arch collapses and a *valgus deformity results*. This valgus is due to two factors:

1. The transverse arch of the foot, normally maintained by the tendon of the peroneus longus (fig. 81), becomes flattened (fig. 82); at the same time the medial arch is lowered: the forefoot (e) rotates medially on its long axis so that the sole of the foot touches the ground over its whole surface and simultaneously the forefoot is displaced (d) laterally.
2. The calcaneus turns on its long axis in the direction of pronation (fig. 83) and tends to lie flat on its medial surface. This degree of valgus, which is visible and can be measured by the angle between the axis of the heel and the Achilles tendon, exceeds the physiological limits (5°) and can attain 20° in certain cases. According to some authors, this valgus deformity is due primarily to a malformation of the articular surfaces of the subtalar joint and an abnormal measure of laxity of the interosseous ligaments; other authors believe these lesions to be secondary.

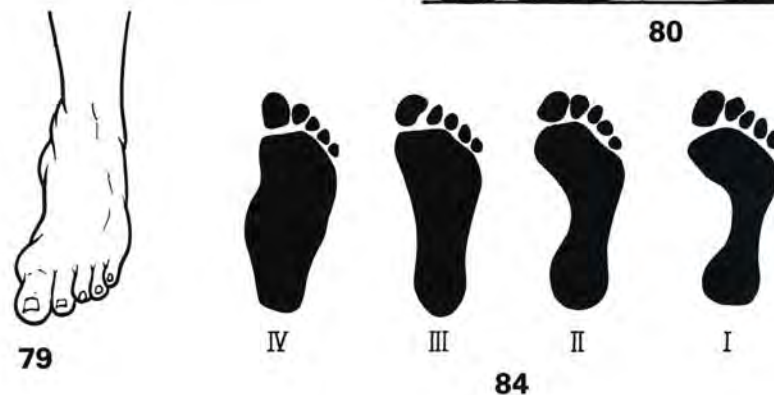
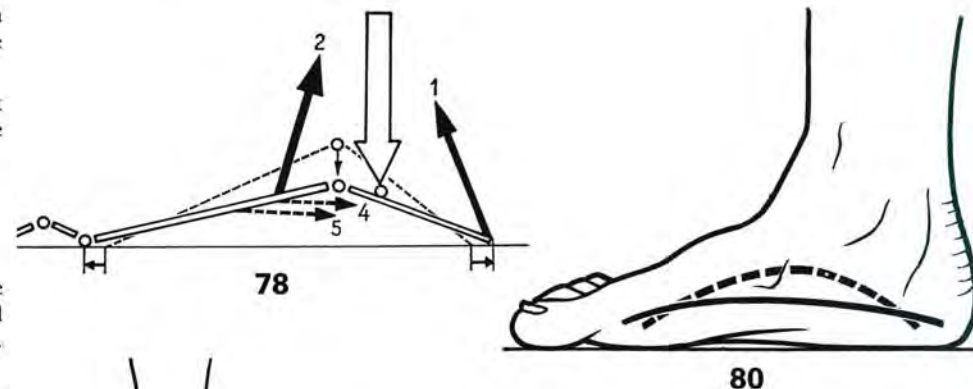
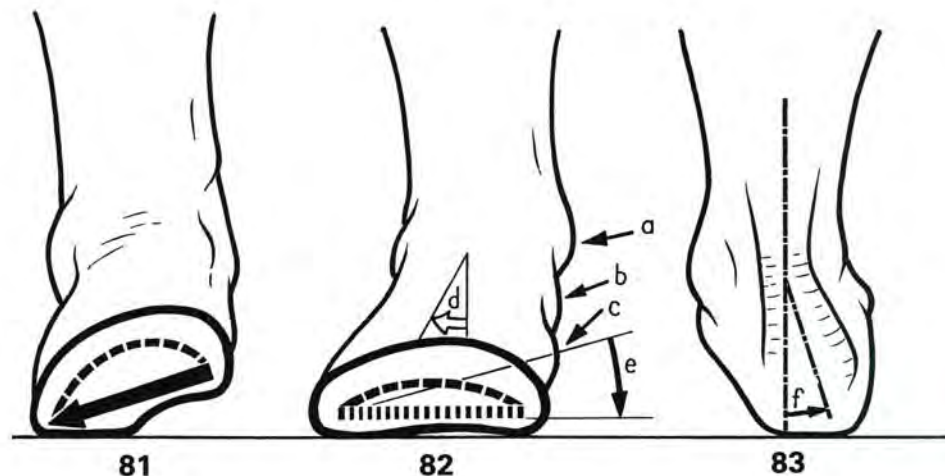
Whatever the cause, this valgus displaces the centre of stress towards the medial border of the foot and the talar head moves inferiorly and medially. The medial margin of the foot then shows the presence of three more or less distinct *projections* (fig. 82):

- the medial malleolus (a), abnormally prominent;
- the medial part of the head of the talus (b);
- the tubercle of the navicular bone (c).

The tubercle of the navicular represents the apex of the obtuse angle formed by the axes of the posterior and anterior parts of the foot: adduction-pronation of the posterior part is compensated by abduction-supination of the anterior part, so that the curvature of the vault is flattened out. (Hohmann, Boehler, Hauser, Delchef, Soeur).

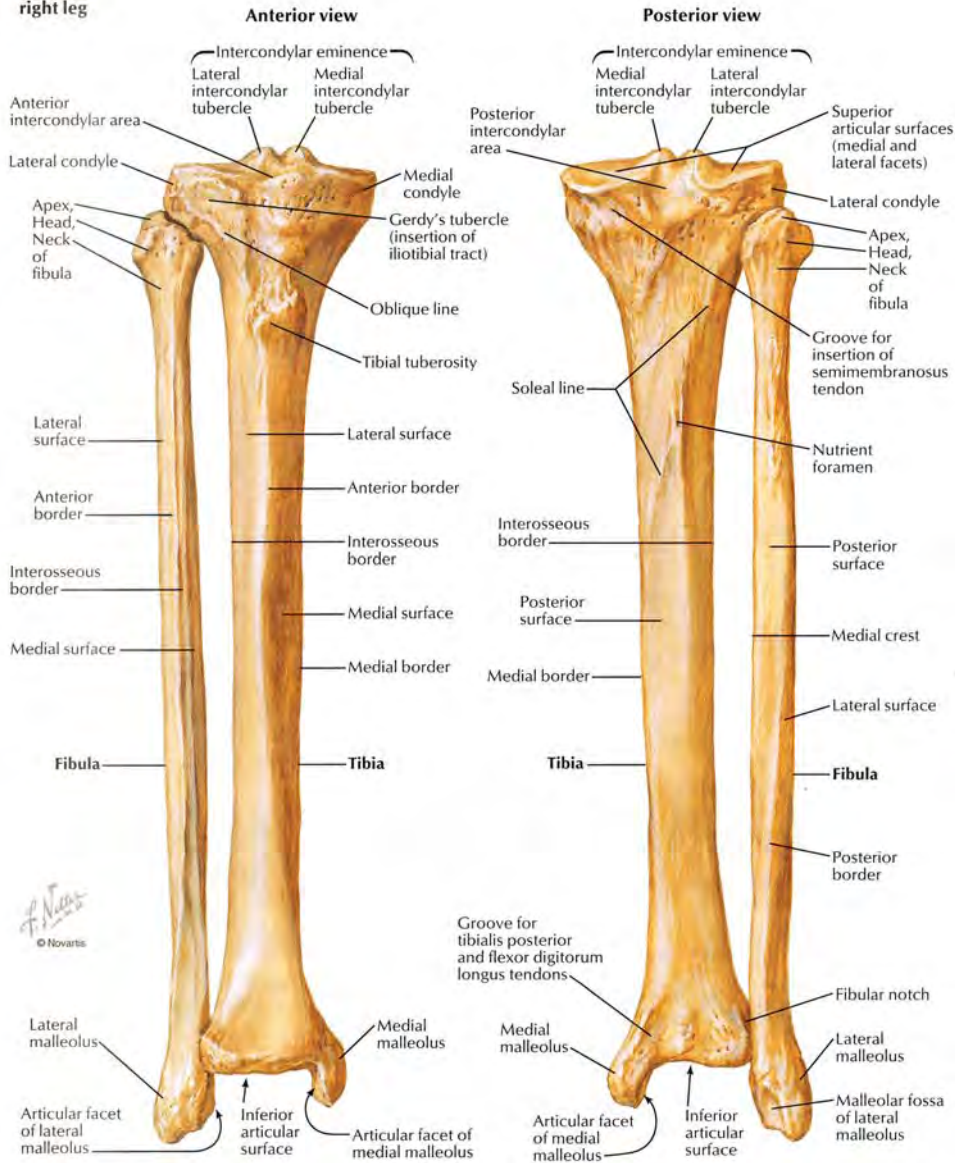
This complex of deformities has already been described when the static changes of the plantar vault were studied (p. 227, fig. 41). (In this case, they are less marked.) It is a relatively common condition, known as *the painful flat foot or tarsalgia of the young*.

The diagnosis of flat foot is made easier with the use of the **footprint** (fig. 84): in comparison with the normal footprint (I), the concavity of the medial border of the foot is gradually filled out (II and III) until in long-standing cases (IV) the medial border may even become convex.



Tibia and Fibula

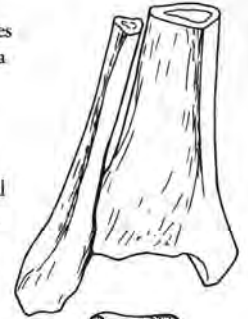Bones of right leg



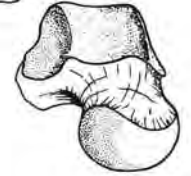Joints

Ankle joint

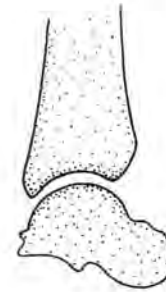
Seen from the front, this joint resembles a pincer or monkey wrench gripping a section of a hemisphere.



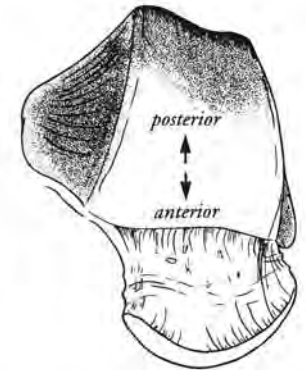
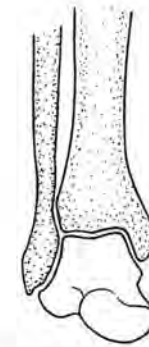
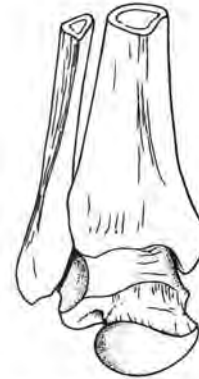The lateral and medial malleoli, and distal tibia, fit against the three facets of the talar body (right).



Seen from the side, the cartilaginous superior and inferior articulating surfaces appear concave and convex, respectively (left).



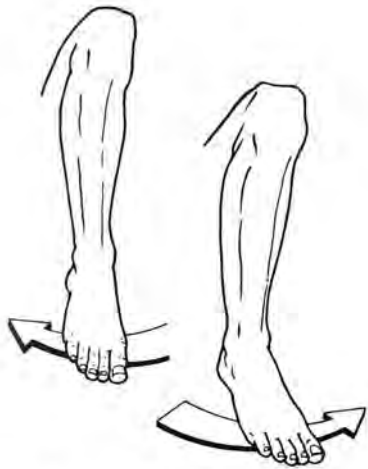
SUPERIOR VIEW:



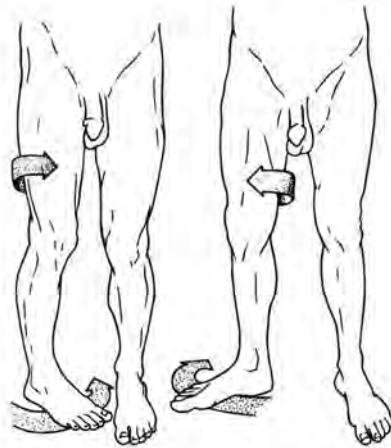
The two malleoli provide a snug fit around the talus. The lateral malleolus extends farther down and is more obliquely oriented than the medial malleolus.

In cross-section, we see that there is a slight ridge on the articulating surface of the distal tibia, and corresponding groove on talus.

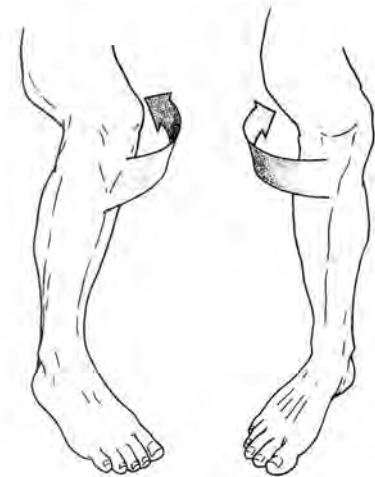
We should also note that the superior talus is wider anteriorly than posteriorly.



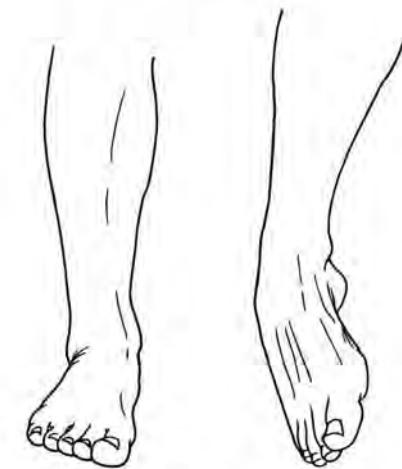
In **abduction** and **adduction**, the distal end of the foot moves away from and toward the median plane, respectively.



These movements can be amplified by or confused with medial and lateral rotation of the hip (when the knee is extended)...



...or rotation of the flexed knee. In either of these situations, you will notice movement of the tibial tuberosity. Remember that the ankle joint is a pure hinge, capable only of dorsiflexion/plantar flexion. Therefore, abduction/adduction occur at the subtalar and more distal joints.



Eversion, in which the sole of the foot is directed away from the median plane, is a combination of abduction and dorsiflexion.

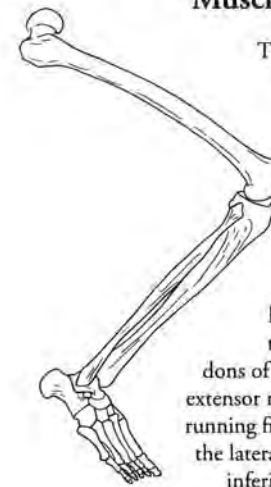
Inversion, in which the sole is directed toward the median plane, is a combination of adduction and plantar flexion.

Muscles

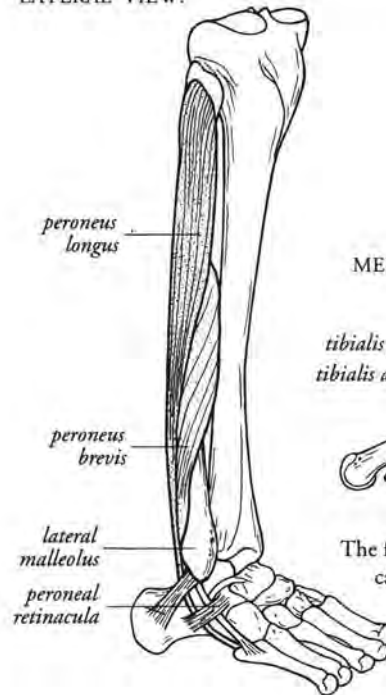
The **extrinsic muscles** of the foot originate on the femur, tibia, or fibula (left), and insert on foot bones via long tendons. They are all polyarticular. The **intrinsic muscles** are short muscles which run between nearby foot bones.

They are mostly on the plantar side of the bones, and comprise the fleshy mass of the sole.

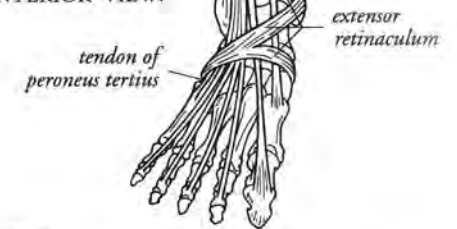
The ankle has an **extensor retinaculum** and **flexor retinaculum**, homologous to the same-named structures of the wrist, to help keep the tendons of certain extrinsic muscles in place. The extensor retinaculum consists of a superior band running from fibula to tibia anteriorly (just above the lateral and medial malleoli), and a Y-shaped inferior band running from calcaneus to the medial malleolus and the medial edge of the plantar aponeurosis (right).



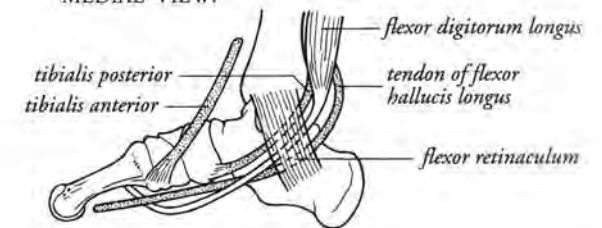
LATERAL VIEW:



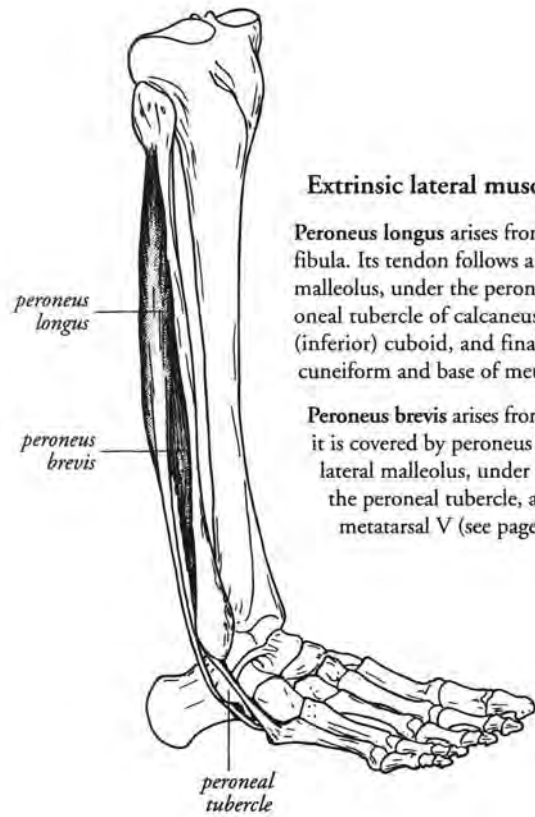
ANTERIOR VIEW:



MEDIAL VIEW:



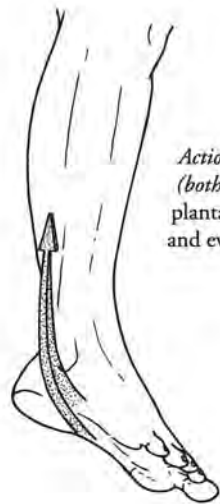
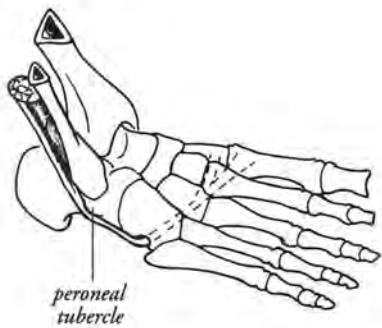
The flexor retinaculum runs from the medial malleolus to calcaneus (above). There is also a **peroneal retinaculum** for the peroneus muscle tendons (left). Its superior band runs from the lateral malleolus to calcaneus, and the inferior band between two spots on the anterolateral calcaneus.



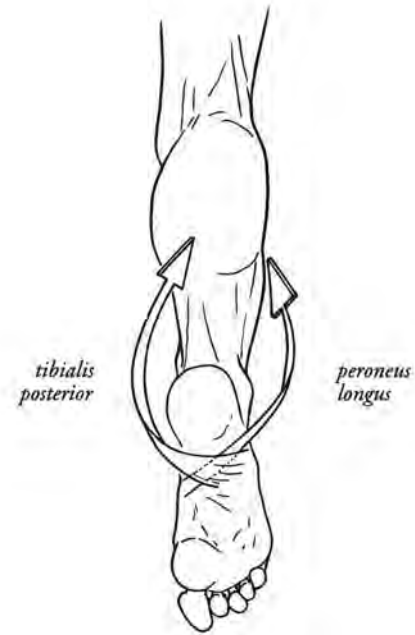
Extrinsic lateral muscles

Peroneus longus arises from the head and superolateral shaft of fibula. Its tendon follows a complicated path behind the lateral malleolus, under the peroneal retinaculum, *inferior* to the peroneal tubercle of calcaneus, along the groove of the plantar (inferior) cuboid, and finally inserts inferiorly on the medial cuneiform and base of metatarsal I (see left and lower left).

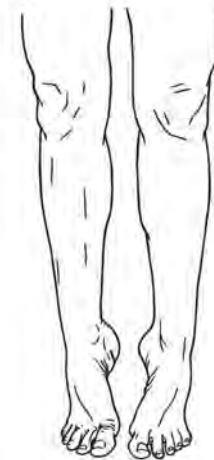
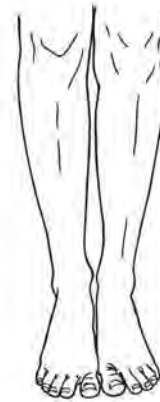Peroneus brevis arises from the inferolateral fibular shaft, where it is covered by peroneus longus. Its tendon passes behind the lateral malleolus, under the peroneal retinaculum, *superior* to the peroneal tubercle, and inserts on the lateral tubercle of metatarsal V (see page 254).



*Actions
(both muscles):
plantar flexion
and eversion*



The tendons of peroneus longus and tibialis posterior (see next page), coming from opposite sides, form a "sling" under the middle part of the foot which is crucial in supporting the arches (above). Peroneus longus and brevis both strengthen and support the lateral arch (the weight-bearing arch; see page 243), stabilizing the ankle and preventing loss of balance laterally when standing, especially when raised on tiptoe (below).



Summary of movements/stability

As in Chapter 6, it will be helpful at this point to summarize the muscles involved in specific movements of the foot. The arrows represent the forces produced by the various muscles.

Dorsiflexion:

- (1) tibialis anterior
- (2) extensor hallucis longus
- (3) extensor digitorum longus
- (4) peroneus tertius

Plantar flexion:

- (1) peroneus longus
- (2) peroneus brevis
- (3) triceps surae
- (4) flexor hallucis longus
- (5) tibialis posterior
- (6) flexor digitorum longus

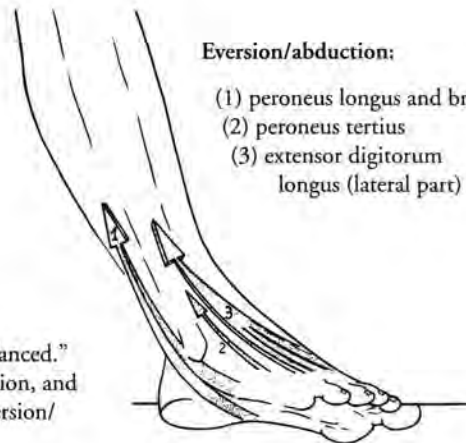
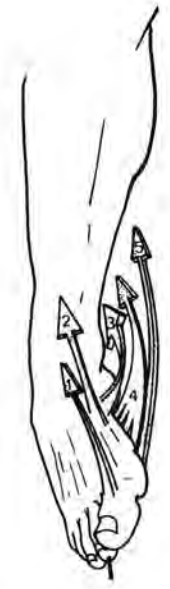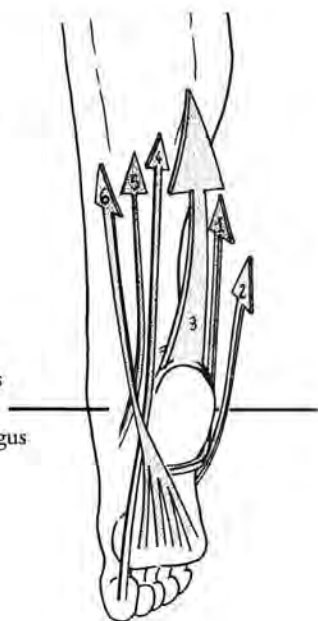
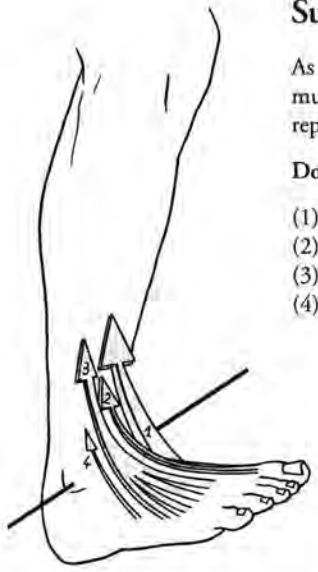
Inversion/adduction:

- (1) extensor hallucis longus
- (2) tibialis anterior
- (3) tibialis posterior
- (4) flexor digitorum longus
- (5) flexor hallucis longus

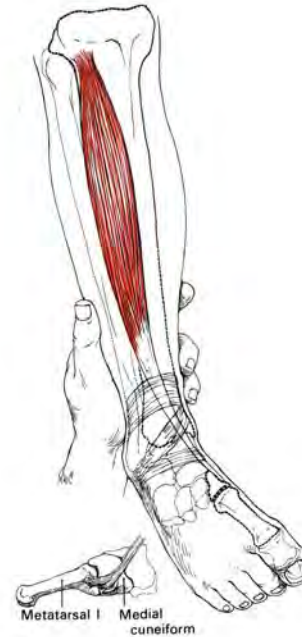
not shown:
triceps surae

Eversion/abduction:

- (1) peroneus longus and brevis
- (2) peroneus tertius
- (3) extensor digitorum longus (lateral part)



Notice that opposing actions are not "balanced." Plantar flexion is dominant over dorsiflexion, and inversion/adduction is dominant over eversion/abduction.



Origin: Lateral condyle and proximal one half of lateral surface of tibia, interosseus membrane, deep fascia, and lateral intermuscular septum.

Insertion: Medial and plantar surface of medial cuneiform bone, base of first metatarsal bone.

Action: Dorsiflexes the ankle joint and assists in inversion of the foot.

Nerve: Deep peroneal, L4, 5, S1.

Patient: Supine or sitting (with knee flexed if any Gastrocnemius tightness is present).

Fixation: The examiner supports the leg just above the ankle joint.

Test: Dorsiflexion of the ankle joint and inversion of the foot, without extension of the great toe.

Pressure: Against the medial side, dorsal surface of the foot, in the direction of plantar flexion of the ankle joint and eversion of the foot.

Weakness: Decreases the ability to dorsiflex the ankle joint and allows a tendency toward eversion of the foot. This may be seen as a partial drop-foot and tendency toward pronation.

Contracture: Dorsiflexion of ankle joint with inversion of the foot, that is, calcaneovarus position of the foot.

Note: Although Tibialis anterior weakness may be found in conjunction with a pronated foot, such weakness is seldom found in a congenital flatfoot.

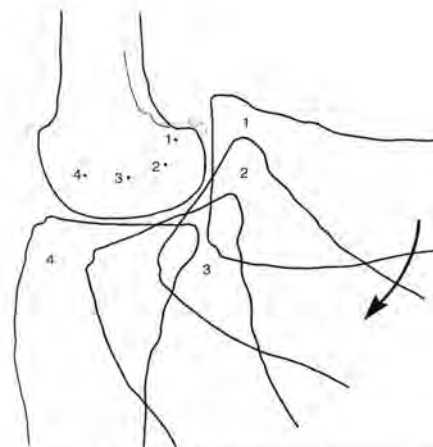
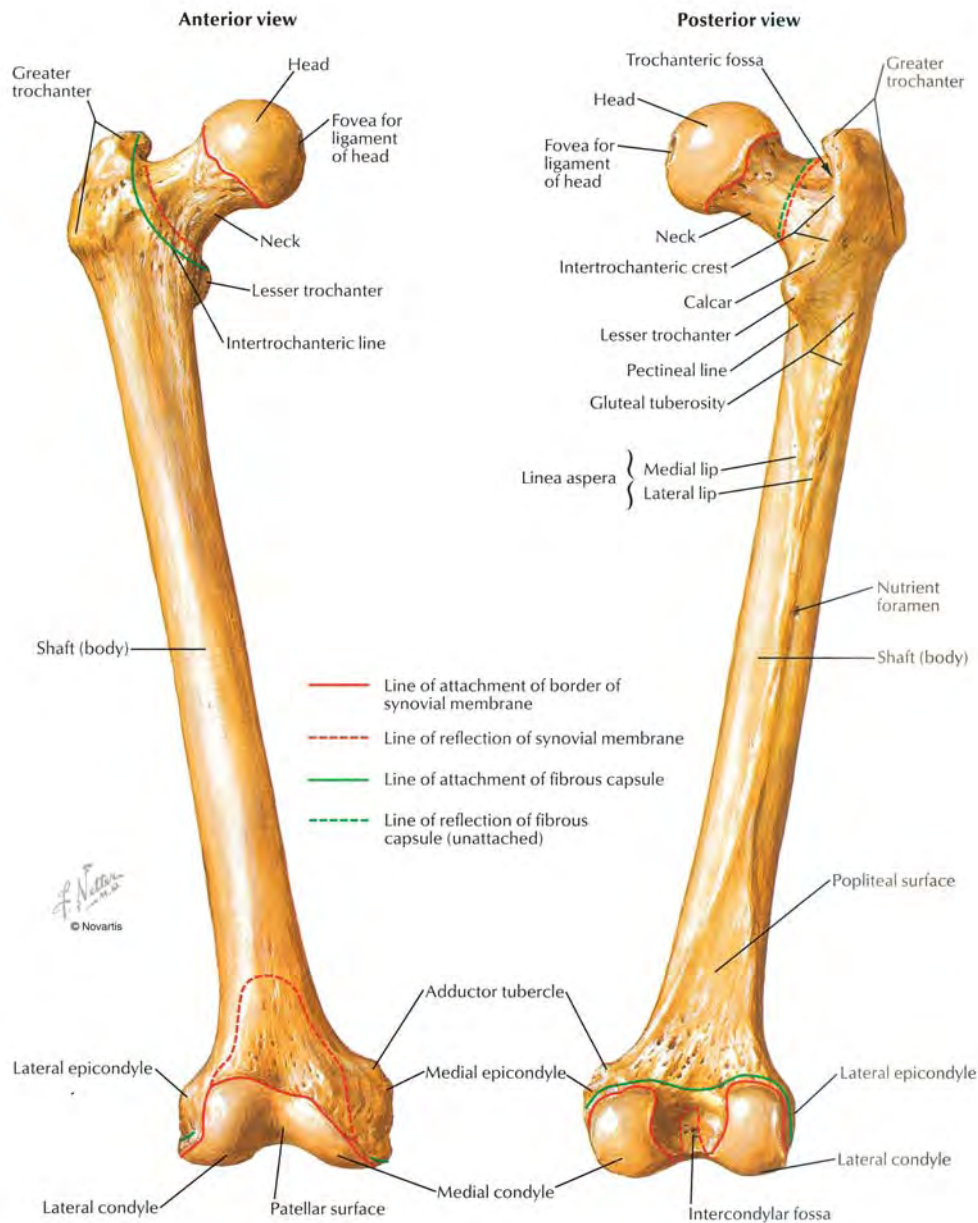


FIG. 13-11. Diagram showing loci of normal instant centers and congruency during flexion and extension of the knee.

ion and extension of the knee occur with a combination of rolling and sliding at the joint surfaces. The closer the instant center is to the contacting joint surfaces, the greater the amount of rolling that occurs at a particular point in the range of movement. An instant center that lies some distance from the contacting surfaces indicates considerable sliding between the surfaces. Because the normal axes of movement for flexion and extension of the knee lie within the condylar region of the femur—not on the joint surfaces or a long distance away—it follows that both sliding and rolling accompany the movement. It can be seen from the loci of normal instant centers that the axis of movement shifts farther away from the joint surface as the knee extends, indicating that relatively more sliding is occurring as extension takes place (see Fig. 13-11).^{77,78} Considering that the tibia moves on the fixed femur, the direction of sliding and rolling of the tibial joint surface is anterior during extension and posterior during flexion.

TRANSVERSE ROTATION

Because the femorotibial joint surfaces are incongruent in all positions except full extension, and because the menisci are semimobile, the knee joint can undergo rotation in the transverse plane. This rotary movement can easily be produced actively or passively with the knee flexed, and is important for attenuation of rotary forces acting on the knee during normal function.

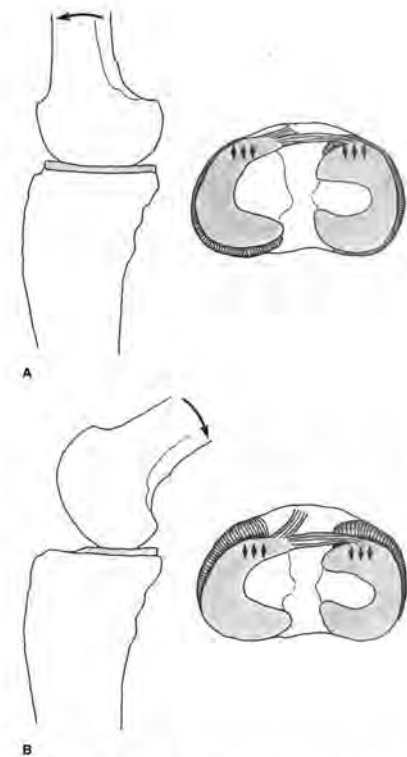


FIG. 13-12. (A) During extension, the menisci glide forward, while (B) during flexion, the menisci recede to conform to the radius of curvature of the connecting femoral condyles.

There is also an automatic, or conjunct, rotation at the knee that accompanies flexion and extension of the joint. This occurs as an external rotation of the tibia relative to the femur during the final 15° to 20° of extension, and an internal tibial rotation during the initial 15° or 20° of flexion from a fully extended position. Because the knee undergoes rotation and the menisci tend to move with the femur, much of the movement occurs between the menisci and the tibia.

Several factors contribute to the occurrence of knee rotation during flexion and extension.^{16,242,263,277} First, and perhaps most important, is the shape and orientation of the medial femoral condyle. Looking at the femur end on, the medial condyle is curved and obliquely oriented, whereas the lateral condyle is situated in the sagittal plane (see Fig. 13-2). Also of signif-

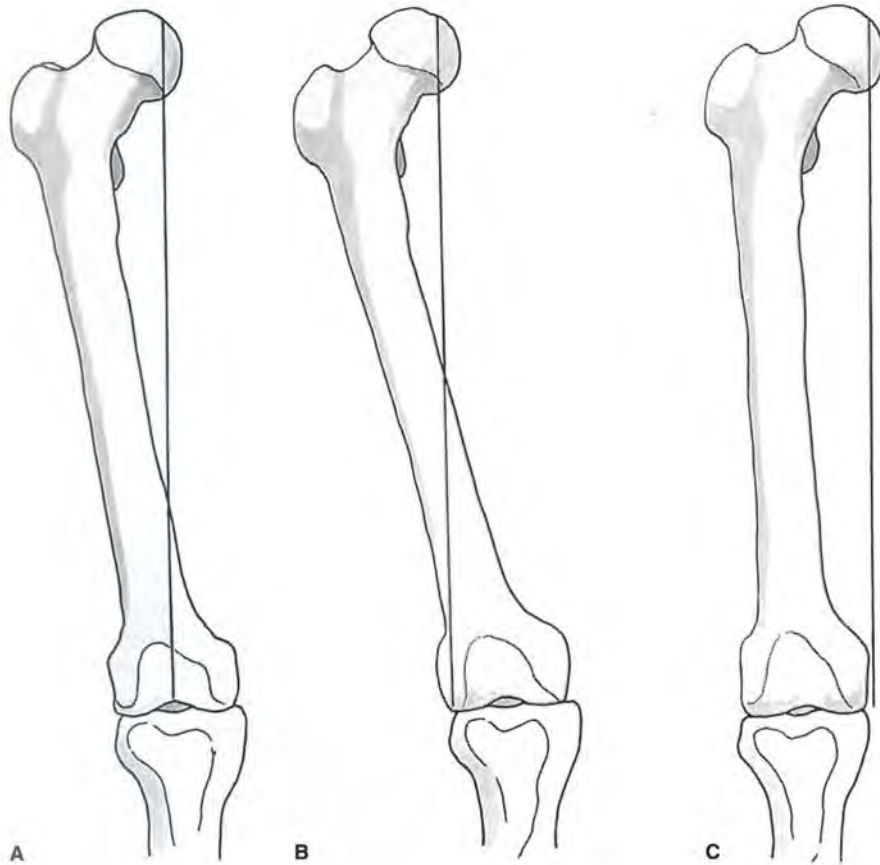


FIG. 13-13. Knee joint angulation showing (A) normal valgus angulation, (B) excessive valgus angulation, and (C) varus angulation.

Anatomy Trains rules they are not a myofascial continuity, they do function as one, but only when the knee is extended. The gastrocnemius heads reach up and around the hamstring tendons to insert onto the upper portions of the femoral condyles. The hamstrings reach down and around the gastrocnemii to attach to the tibia and fibula. As long as the knee is bent, these two myofascial units go their own ways, neighboring but unconnected (Fig. 3.14B). As the knee joint goes into extension, however, the femoral condyles come back into both these myofasciae, tightening the complex and making them function together almost as if they were two pairs of hands gripped at the wrists (Fig. 3.14 A and C).

This provides a long-winded but accurate explanation of why it is less of a stretch to pick up your dropped keys from the floor by flexing your knees rather than keeping them extended (Fig. 3.15). More to the point, it shows us that the entire SBL is a continuity in a regular standing posture. In yoga, for instance, positions (asanas) which utilize a forward bend with straightened legs (as in the downward facing dog, plow, forward bend, or any simple hamstring stretch) will engage the SBL as a whole, whereas forward bends with the knees bent will engage only the upper myofascia of the line.

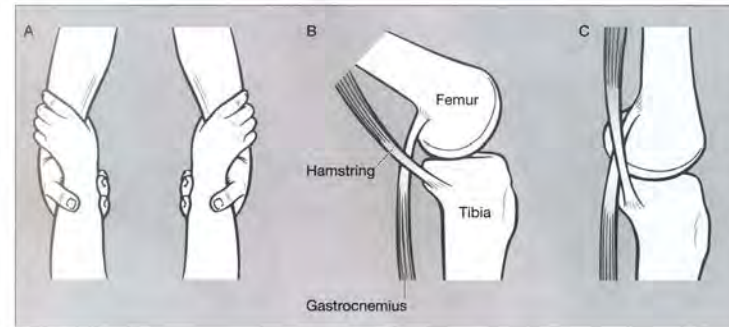


Fig. 3.14 When the knee is flexed, the myofascia of the thigh and the myofascia of the lower leg function separately (B). When the knee is extended, these myofasciae link into one connected functioning unit (C), like the interlocked hands of a pair of trapeze artists (A – compare to Fig. 3.13).

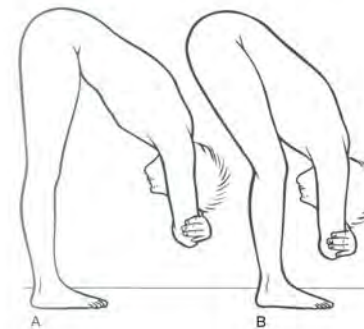


Fig. 3.15 When the knees are bent (B), the upper and lower parts of the SBL are separate, and it is easier to fold at the hips. With the knees extended (A), the SBL is linked into one unit, and a forward bend may not be as easy.

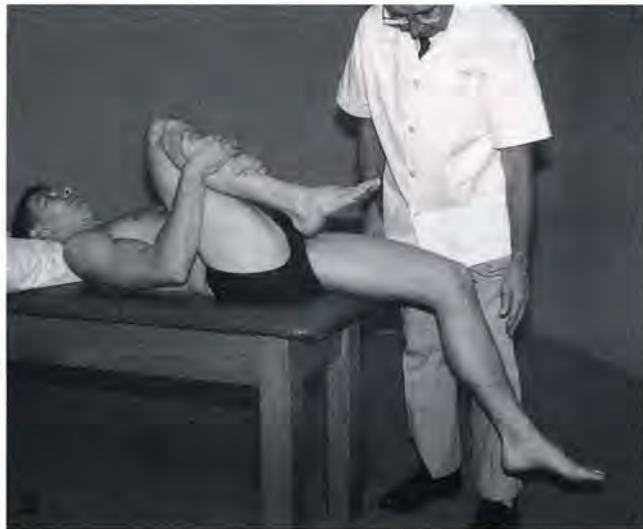

Figure 20.16a.

Rectus femoris muscle.

Length test and manual stretch position supine.

1. Patient supine sitting on end of table with operator standing at end of table.
2. Patient holds leg not being tested in a flexed position with thigh of the tested leg on the table.
3. Operator assesses flexion at the knee. If less than 90° , rectus femoris shortness is present.
4. If short and tight, operator resists a 5- to 7-second contraction of knee extension, for five to seven repetitions, with the operator increasing knee flexion after each patient effort.

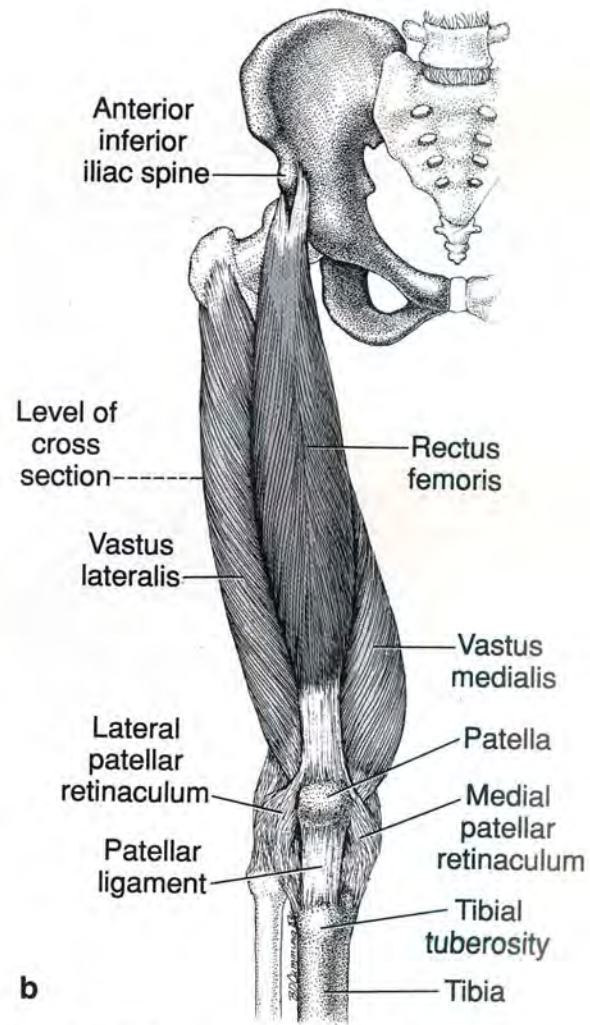


Figure 20.16b.

Attachments (front view) of the right rectus femoris muscle in relation to the vastus lateralis and vastus medialis muscles.

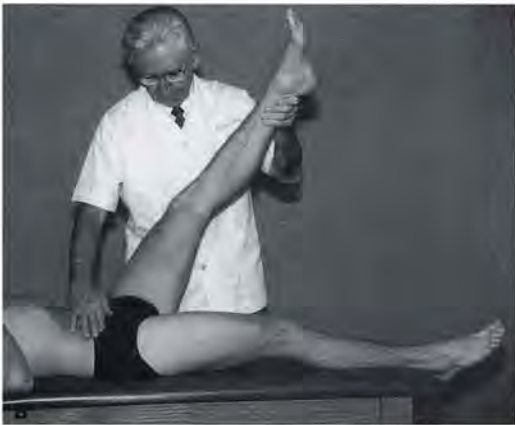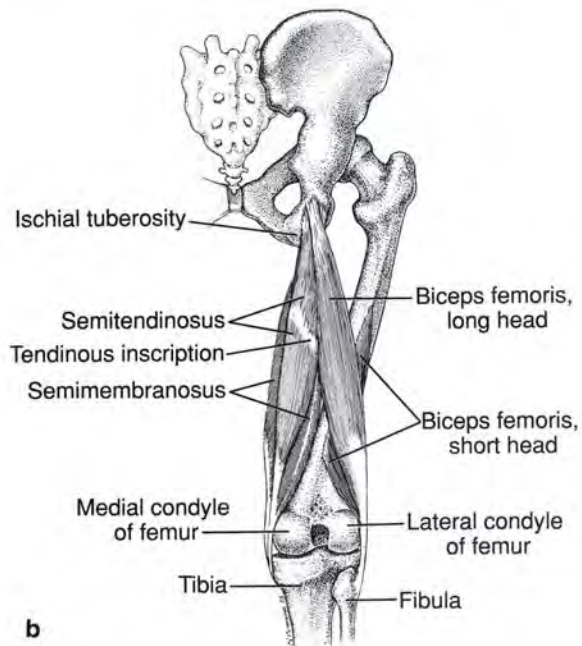


Figure 20.22 a and b.

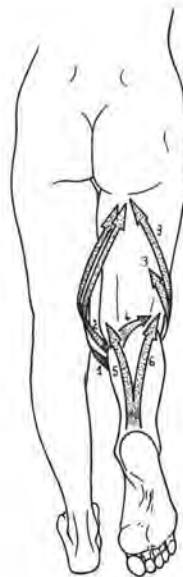
Hamstring muscles.

Length test and manual stretch position supine.

1. Patient supine on table with operator standing on same side as leg being tested.
2. Operator monitors the opposite anterior superior iliac spine while lifting the tested leg to the barrier of hip flexion. Comparison is made with the opposite side. If asymmetric, shortness and tightness is present in the involved hamstring muscles.
3. Operator performs the test with the leg adducted and abducted to test the difference in tightness of the medial and lateral hamstrings.
4. If short and tight, operator resists a 5- to 7-second patient effort of hip extension for five to seven repetitions with the operator engaging a new barrier after each effort.

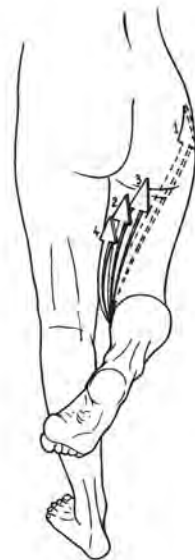

b



Flexion of knee (left):

- (1) semitendinosus
 - (2) semimembranosus
 - (3) biceps femoris
 - (4) popliteus
 - (5, 6) gastrocnemius
- not shown:*
sartorius, gracilis

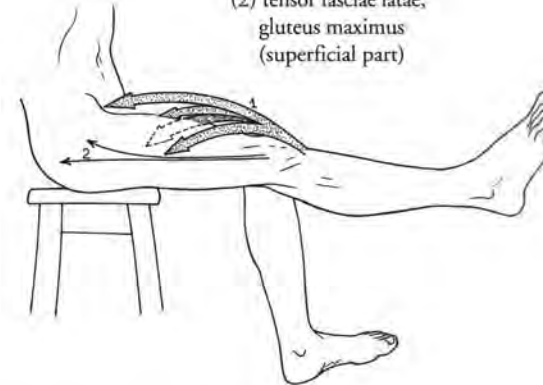

Medial rotation of knee (left):

- (1) sartorius
 - (2) semitendinosus
 - (3) semimembranosus
 - (4) gracilis
- not shown:*
popliteus

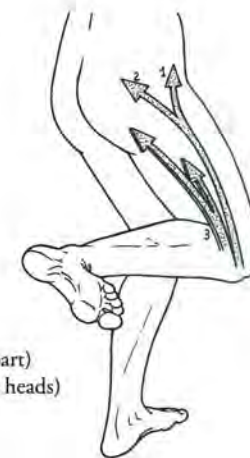Extension of knee (below):

- (1) quadriceps femoris
- (2) tensor fasciae latae, gluteus maximus (superficial part)



Lateral rotation of knee (right):

- (1) tensor fasciae latae
- (2) gluteus maximus (superficial part)
- (3) biceps femoris (long and short heads)



BIBLIOGRAPHY

Anatomy of Movement by Blandine Calais-Germain, 1993

Anatomy Trains by Thomas Myers, 2003

Atlas of Human Anatomy, 2nd edition by Frank Netter, M.D., 2000

Dance Kinesiology by Sally Fitt, 1988

Dynamic Alignment through Imagery by Eric Franklin, 1996

Management of Common Musculoskeletal Disorders, 3rd edition by Darlene Hertling and Randolph Kessler, 1996

Muscles Testing and Function, 4th edition by Kendall, McCreary, and Provance, 1993

The Physiology of the Joints, Volumes 1 & 2, 5th editions by I.A. Kapandji, 1982 & 1987

Principles of Manual Medicine, 2nd edition by Philip E. Greenman, 1996